

1-1-1966

Cutaneous nerves of the trunk of the domestic pig with special reference to the spinal nerves.

Sham Sunder Gandhi
Iowa State University

Follow this and additional works at: <https://lib.dr.iastate.edu/rtd>

 Part of the [Veterinary Anatomy Commons](#)

Recommended Citation

Gandhi, Sham Sunder, "Cutaneous nerves of the trunk of the domestic pig with special reference to the spinal nerves." (1966).
Retrospective Theses and Dissertations. 18223.
<https://lib.dr.iastate.edu/rtd/18223>

This Thesis is brought to you for free and open access by the Iowa State University Capstones, Theses and Dissertations at Iowa State University Digital Repository. It has been accepted for inclusion in Retrospective Theses and Dissertations by an authorized administrator of Iowa State University Digital Repository. For more information, please contact digirep@iastate.edu.

100

CUTANEOUS NERVES OF THE TRUNK OF THE
DOMESTIC PIG
WITH SPECIAL REFERENCE TO THE SPINAL NERVES

SF767
59
G1510
C.2

by

Sham Sunder Gandhi

A Thesis Submitted to the
Graduate Faculty in Partial Fulfillment of
The Requirements for the Degree of
MASTER OF SCIENCE

Major Subject: Veterinary Anatomy

Signatures have been redacted for privacy

Iowa State University
Of Science and Technology
Ames, Iowa

1966

1484969

1126-5

TABLE OF CONTENTS

	Page
I. INTRODUCTION	1
II. REVIEW OF LITERATURE	3
III. MATERIAL AND METHODS	36
IV. RESULTS	40
V. DISCUSSION	111
VI. SUMMARY AND CONCLUSIONS	132
VII. BIBLIOGRAPHY	146
VIII. ACKNOWLEDGEMENTS	151
IX. APPENDIX A	153a
X. APPENDIX B	169

I. INTRODUCTION

There appears to be little information available in the literature regarding the pattern of cutaneous innervation in the domestic pig, or other domestic animals except for the dog (Miller, Christensen, Evans, 1964) and the horse (Barone, 1964). Therefore, it was felt necessary to investigate this area to fill the lacuna which exists in the literature and to supplement the fragmentary and inconclusive comparative references available in textbooks with complete and detailed information of this area. The studies have been directed to the cervical, thoracic, lumbar, sacral and coccygeal regions. It is hoped that the information gathered will be of practical use in applied anatomy, regional anesthesia and clinical diagnosis, etc.

Studies have been conducted to investigate all cutaneous nerves arising from the spinal nerves of the cervical, thoracic, lumbar, sacral, and coccygeal regions, except for those arising from the brachial and lumbosacral plexuses; however, branches which were found to be intimately associated in the innervation of the skin of the regions under study have been described, where necessary. The results obtained show, in general, the pattern of origin, branching, distribution, and area of ramification of the cutaneous nerves of the different regions with their most common variations. All the studies

have been carried out by way of gross dissections only, and no experimental investigations have been undertaken. No attempt has been made to study the autonomic nervous system in relation to the cutaneous innervation.

As no authoratative account of the nomenclature of the peripheral nervous system is available, the current applicable nomenclature has been used, with modifications as suggested by Dr. Robert Getty. Moreover, Leutert's 1963 compilation, together with part of the *Nomina Anatomica Veterinaria*, has been consulted wherever appropriate.

II. REVIEW OF LITERATURE

As stated in the introduction, a search of the existing literature revealed little information regarding the spinal nerves of the domestic pig, in general, and there is practically no information about their cutaneous branches. However, information available in the existing textbooks was utilized (Ellenberger and Baum, 1943; Chauveau and Arloing, 1902; Montané and Bourdelle, 1920; Patten, 1948; and Sisson and Grossman, 1953). There are only a few comparative comments regarding the spinal nerves of the pig in these textbooks, except in Montané and Bourdelle, (1920), who described them in a little more detail. The problem can be summed up in the words of Hughes (1960), who described the skin of the dog in detail, including histological studies and blood supply, etc. He commented that as far as the innervation is concerned it is disappointing to note that little attention has been paid to this area in the case of the domestic animals though a great deal of work has been done in man, and he concludes with the hope that in coming years due attention will be paid to this area. Therefore, bearing in mind that the studies were initiated with a view to establish a basis for applicability of the findings for day-to-day practice, much information concerning other animals have been employed and an

attempt has been made to make a complete comparative review of the literature regarding the innervation of the skin of all the domestic animals.

The innervation of the skin in the domesticated animals attracted the attention of workers as early as 1898 when a series of general investigations were carried out by Bolk (1898-1899) on the subject. Various other workers then started investigations taking into consideration a particular species and a particular region of said species. As far as the comparative studies are concerned good work has been done by Dozsa (1939), Schreiber and Schaller (1954), Rzhantisyna (1958) and a number of others. Much of the work done on the innervation of the skin of the horse was done by Grau (1935 and 1937), Barone and Schellenberg (1951), Sisson and Grossman (1953) and Seiferle (1939). A number of workers have investigated the cutaneous innervation of cattle, but prominent among them are the works of Walter (1959), Koch (1954), Farquharson (1940), Reimers (1913), Schaller (1956), and Arnold and Kitchell (1957). Most of these are studies of the innervation of the abdominal wall with the cutaneous branches having been traced during the studies on lumbar or paravertebral anesthesia. The cutaneous branches of the lumbar and sacral nerves were traced by the workers studying the lumbosacral plexus. Polyakov (1959), and May (1964)

have studied the innervation of the skin of the sheep and goat. As far as the dog and cat are concerned, voluminous material is available on the subject as these are the two main species of domesticated animals on which the investigations of the tactile dermatome have been carried out and for which the cutaneous areas of the skin have been mapped out. Arnold and Kitchell (1957) carried out this type of study in cattle and investigated the areas of the abdominal wall. In the cat, most of the work was done by Kuhn (1953), and Hekmatpanah (1961). Various workers have done work on the innervation of the skin in the dog. Prominent among them are: Bernhard (1962), Dusser de Barenne (1911), Sussdorf (1889), Sisson and Grossman (1953) and lately by Miller, et al. (1964). As far as the innervation of the skin of the domestic pig is concerned there is practically no information available in the English literature. Sinclair (1937) has done some studies in relation to the spinal cord and its nerves but has not gone into any detail. Later on Jankovic (1954) studied the topography of the spinal cord of the pig. Studies on the cutaneous innervation have been made by Reimers (1913) and Schneider and Zintzsch (1962). References have been made about the innervation of the skin by various authors of books on the comparative anatomy of domesticated animals.

The cutaneous nerve supply is mainly from the spinal nerves, which originate from the spinal cord in all the domestic animals. These spinal nerves are responsible for the innervation of various organs, muscles, and the various regions of the skin. Embryologically, the neural tube develops into a definitive spinal cord after passing through a series of intermediary developmental stages. In the neural tube, the various cells and their processes arrange themselves into three layers, ependymal, mantle and marginal. There is a continued cell proliferation resulting in thickenings at the anterior and posterior ends of the mantle layer followed by a series of changes ultimately transforming the neural tube into the characteristic gray and white matter of a definite spinal cord.

Investigations have been made by a large number of workers regarding the topography of the spinal cord in various domesticated animals. The spinal cord has been divided into five different parts with the spinal nerves innervating that particular part of the body originating from the corresponding part of the spinal cord. A comparative study has been made by Goller (1959) on the various parts of the spinal cord, the area of their extension in the body and the various spinal nerves originating from it. The extension of the various parts of the spinal cord and the spinal nerves originating from them is as follows in the domesticated animals:

Horse - according to Seiferle (1939):

Pars cervicalis extends from the foramen magnum of the occipital bone to the second third of the first thoracic vertebra (C_1 to C_8).

Pars thoracalis from the caudal one sixth of the first thoracic vertebra to the cranial third of the first lumbar vertebra (Th_1 to Th_{18}).

Pars lumbalis between the first third of the first lumbar vertebra to the cranial border of the sixth lumbar vertebra (L_1 to L_6).

Pars sacralis lies in the sixth lumbar vertebra and in the cranial half of the first sacral vertebra (S_1 to S_5).

Cattle - according to Seiferle (1939):

Pars cervicalis - from the foramen magnum of the occipital bone to the cranial border of the first thoracic vertebra (C_1 to C_8)

Pars thoracalis - cranial border of the first thoracic vertebra to the limit between the last thoracic and first lumbar vertebrae (Th_1 to Th_{13})

Pars lumbalis - cranial border of the first lumbar vertebra to the caudal border of the fifth lumbar vertebra (L_1 to L_6)

Pars sacralis lies between the caudal border of the fifth and the caudal fourth of the sixth lumbar vertebra (S_1 to S_5).

Pars coccygealis lies between the caudal fourth of the sixth lumbar vertebra and extends to the vertebral articulation cranial to the sacrum.

Dog - according to Thiel (1941):

Pars cervicalis - from the foremen magnum to the caudal fourth of the seventh cervical vertebra (C_1 to C_8)

Pars thoracalis lies between the caudal fourth to the seventh cervical and the cranial border of the first lumbar vertebra (Th_1 to Th_{13})

Pars lumbalis - from the cranial border of the first lumbar to the middle of the seventh lumbar vertebra (L_1 to L_7)

Pars sacralis - from the middle of the seventh lumbar to the cranial third of the sacrum (S_1 to S_3)

Pars coccygealis - caudal two thirds of the sacrum

Fig - according to Jankovic (1954):

Pars cervicalis - from the foramen magnum to the cranial border of the first thoracic vertebra (C_1 to C_8)

Pars thoracalis - the thoracic and first lumbar segments lie within the corresponding number of vertebra. At first the caudal lumbar segments show further cranial displacement.

(Th_1 to Th_{14} and Pars lumbalis L_1 to L_6)

Pars sacralis - from the cranial border of L_6 to the cranial third of the second sacral vertebra (S_1 to S_4)

Pars coccygealis lies in the caudal two thirds of S_2 and S_3 .

Sheep - according to Goller (1959):

Pars cervicalis - from the foramen magnum to the middle of C₇ vertebra (C₁ to C₈)

Pars thoracalis - from the middle of C₇ to the first fourth of L₁ (Th₁ to Th₁₃)

Pars lumbalis - from the second fourth of L₁ to the first fourth of L₅ (L₅ to L₆)

Pars sacralis - from the last fourth of the fifth lumbar and in the sixth lumbar vertebra (S₁ to S₄)

Pars coccygealis - cranial half of the first sacral vertebra

These spinal nerves connect the various parts of the body to the spinal cord. In the case of the pig, Sinclair (1937), while tracing the origin of the spinal cord and the formation and distribution of the spinal nerves, described the spinal cord as a thick-walled, tubular structure lying in the vertebral canal. It has been differentiated into gray and white matter forming the central and peripheral parts, respectively. This wall is perforated at the caudal margin of each neural arch by a spinal nerve which is derived from two spinal roots. The dorsal sensory or afferent root arises from the sulcus or groove on the dorsolateral border of the cord and is joined by a ventral motor

or efferent root derived from the sulcus on the ventrolateral margin of this cord. This constitutes a typical spinal nerve which passes out through a notch at the back of each neural or vertebral arch. After emergence, each spinal nerve divides into two branches: the dorsal or epiaxial ramus which passes to the epiaxial trunk, extensors and to the skin of the back; and a sympathetic ramus ventrally known as the ventral or hypaxial ramus which continues into the somatic wall. On the lateral wall it gives rise to a lateral division which innervates the muscles of the trunk and the overlying skin. The ventral division continues to the ventral wall and supplies the muscles and skin of this region. Sinclair (1937) states that the arrangement and pattern of distribution are similar to that of man. The distribution of root fibers retains the segmental order on the surface of the various muscles and skin. The origin, arrangement, distribution, and the basic pattern of branching and innervation are practically the same in all the domesticated animals, though there are many variations as far as the further branching and distribution of the ventral and dorsal branches are concerned. The number of spinal nerves varies from species to species though it usually corresponds to the number of vertebrae present in that particular species. The total number of spinal nerves in the various animals have been tabulated below:

<u>Author</u>	<u>Species</u>	
Seiferle (1939)	Horse	Eight cervical, eighteen thoracic, six lumbar, five sacral, and five coccygeal; totaling 42 pairs.
Seiferle (1939)	Cattle	Eight cervical, thirteen thoracic, six lumbar, five sacral, and five coccygeal; totaling 37 pairs.
Thiel (1941)	Dog	Eight cervical, thirteen thoracic, seven lumbar, three sacral, variable coccygeal (five to seven); totaling 36 to 38 pairs. Commonly, coccygeal are five pairs and total number of spinal nerves is 36 pairs (Miller et al. 1964).
Goller (1959)	Sheep	Eight cervical, thirteen thoracic, six lumbar, four sacral, variable coccygeal; totaling 31 pairs exclusive of the coccygeal nerves.
Jankovic (1954)	Pig	Eight cervical, fourteen thoracic (variable), seven lumbar (variable), four sacral, and variable coccygeal (two to three); totaling 35 to 36 pairs.

The spinal nerves have retained their embryological segmental plan of distribution and innervation while the structures and muscles they innervate have mostly lost their embryological characteristics. This does not mean that all the dorsal and ventral rami of the spinal nerves give branches for the innervation of the skin but most of them give off the cutaneous branches which ramify in the different regions of the skin. The cervical nerves give off some cutaneous branches for the innervation of

the neck, similarly the thoracic lumbar, sacral and coccygeal nerves give some cutaneous branches for the innervation of the skin of the corresponding region of the body.

A. Cervical Cutaneous Nerves

The skin of the neck region is innervated by the various branches arising from the dorsal and ventral rami of the cervical nerves. Various authors have established that there are eight cervical nerves in all the domesticated animals; Seiferle (1939) in the horse and cattle; Thiel (1941) in the dog; Goller (1959) in sheep and Jankovic (1954) in the pig; and many other authors who had investigated in the earlier years. In general the number of spinal nerves corresponds to the number of vertebrae present in that particular region but the cervical and coccygeal regions are exceptions to this generalized statement as the number of cervical vertebrae is seven in all the domesticated animals while the cervical nerves are eight in number. Therefore, the cervical nerves lie anterior to the vertebra with the corresponding number. The first cervical nerve in the dog, according to Miller et al. (1964), and in cattle and the horse, according to Sisson and Grossman (1953), arises from the first segment of the spinal cord just caudal to the foramen magnum of the occipital bone.

It emerges from the intervertebral foramen of the atlas with the pattern being similar in all other cervical nerves, except the eighth cervical nerve which emerges between the last cervical and first thoracic vertebrae. According to various authors mentioned above, the cervical nerves, after emerging from the intervertebral foramen, divide into dorsal and ventral rami. The dorsal ramus again divides into dorsomedial and dorsolateral branches. In the case of the dog, according to Miller et al. (1964), all the branches of the cervical nerves do not give cutaneous branches. The first cervical does not give any cutaneous branch and the dorsal ramus does not divide into dorsomedial and dorsolateral branches. In the case of the dog, the innervation of the skin of the neck is mainly accomplished by the dorsal and ventral branches of the second, third and fourth cervical nerves, which, in turn, give off cutaneous branches which ramify in the skin of the region. The sixth, seventh, and eighth cervical nerves help in the formation of the brachial plexus which may give cutaneous branches for the innervation of the skin of the shoulder region or in surrounding areas. The dorsal branch of the second cervical, during its course through the obliquus capitis caudalis and other muscles, gives off muscular branches which supply the skin of the caudal portion of the temporal muscle and base of the pinna. The ventral branch of the second cervical nerve

runs caudoventrally and during its course gives off transverse cervical branches which innervate the skin of the mandibular space and its adjoining area. The dorsal and ventral branches of the third and fourth cervical nerves further divide into dorsomedial, dorsolateral, ventromedial and ventrolateral branches, respectively. The dorsomedial branches of the third and fourth cervical nerves again divide into cranial and caudal branches which are responsible bilaterally for the innervation of the loose thick skin of the dorsal and adjacent portions of the neck. The dorsolateral branches do not give cutaneous branches. The ventromedial branches are very small and do not give branches for the skin. The ventrolateral branches, during their course, give off large lateral cutaneous branches which innervate the skin of the ventrolateral part of the neck. The second, third and fourth cervical nerves do not have any connection between them, in the case of the dog, and so there is no cervical plexus formed in this species.

In the horse a great deal of work has been done by Grau (1935 and 1937), Barone and Chayer (1950) and Barone and Schellenberg (1951) and Sisson and Grossman (1953). The general pattern of branching is similar to that described for the dog. The first cervical nerve does not innervate the skin, but the dorsal branch divides further into two

branches, a medial and a lateral branch. The main innervation of the skin of the neck is from the branches of the second, third, fourth, and fifth cervical nerves. The dorsal branch of the second cervical nerve innervates the skin of the poll region. The ventral branch gives off cutaneous branch called the cutaneous nerve of the neck, which innervates the mandibular space and adjoining area. The second, third, fourth, and fifth cervical nerves give off anastomosing twigs and form a sort of cervical plexus. The dorsal and ventral branches of the third, fourth and fifth cervical nerves give off the cutaneous branches which innervate the various portions of the skin. The sixth, seventh and eighth cervical nerves, during their course, give cutaneous branches which innervate the shoulder joint and the arm region.

The pattern of innervation is the same in cattle as described in the horse and there is the formation of a cervical plexus.

In the case of the cat, studies have been done for the investigation of tactile dermatomes by the electric resistance method of Kuhn (1953) and Hekmatpanah (1961). They found that the skin of the neck is mainly innervated by branches of the first, second, third and fourth cervical nerves, though in some cases they recorded a negative response in the case of the first cervical nerve.

The pattern of innervation in the pig has been described by Sinclair (1937) to be the same as that of man. The books on comparative anatomy indicate that there is very little difference from the pattern or manner of distribution which exists in cattle. Independent studies have not been carried out as far as the innervation of the skin of the neck is concerned. However, Montané and Bourdelle (1920) mention that there are eight pairs of cervical spinal nerves and each divides into a superior and inferior branch. The inferior branches have strong ramifications and form the superficial cervical plexus. These branches are reinforced by the branches of the spinal accessory nerve. The inferior branches of the last three pairs of cervical nerves and first pair of thoracic nerves are united on each side to form the brachial plexus.

B. Thoracic Cutaneous Nerves

The thoracic region of the skin is mainly innervated by the thoracic nerves. The number of thoracic nerves varies from species to species depending upon the number of thoracic vertebrae. As there are commonly fourteen to sixteen thoracic vertebrae in the case of the pig there are fourteen to sixteen pairs of thoracic nerves. Similarly, in the case of cattle, sheep, goats, dogs and cats there are thirteen pairs of thoracic nerves while in the case of the horse there are eighteen

pairs of thoracic nerves. Each thoracic nerve which lies posterior to the corresponding thoracic vertebra, after coming out of its intervertebral foramen, divides into dorsal and ventral roots. These roots further give a number of branches, varying from species to species, which constitute the innervation of the thoracic region.

According to Barone (1964), and Sisson and Grossman (1953) the dorsal branches divide into medial and lateral branches; the medial branches mainly constitute the innervation of the muscles while the lateral branches innervate the skin by dividing into two branches -- one ascending dorso-medially toward the dorsal spine and the other traversing laterally. According to Barone (1964), the ventral branches or the intercostal nerves, except the first one, give off one lateral cutaneous branch which further subdivides into a number of cutaneous branches out of which two are the principal cutaneous branches. These branches anastomose with the lateral thoracic nerve forming a rich plexus which is distributed to the skin of the great part of the trunk. The intercostal nerves terminate as the ventral cutaneous branches. According to Sisson and Grossman (1953) in the case of the horse, the intercostal nerves give off three series of cutaneous branches: the dorsal series emerges through the *M. longissimus dorsi* and the lumbodorsal fascia; the middle ones perforate the *M. serratus*

ventralis thoracis, Mm. intercostales externi and the M. obliquus abdominis externus; and the ventral series pierce the abdominal tunic to supply the skin. The last three nerves supply some part of the flank region.

The innervation of the skin of the trunk of cattle has been investigated in detail by Schaller (1956) and the distribution of the Th₁₁, Th₁₂ and Th₁₃ nerves has been described by studying their dermatomes by Arnold and Kitchell (1957) and Koch (1954). Schaller (1956), states that as typical spinal nerves, the thoracic nerves divide into dorsal and ventral branches. The dorsal branches further subdivide into medial and lateral branches and both terminate as cutaneous branches. In two cases he observed that the dorsal branch of the first thoracic spinal nerve gives off two lateral branches and both of them appear on the surface of the skin. As in the horse, lateral branches again divide into two principal cutaneous branches. The ventral branches, or intercostal nerves, give off lateral cutaneous branches which further subdivide into two cutaneous branches, while the intercostal nerves terminate as ventral cutaneous branches. Sisson and Grossman (1953) state that the thoracic spinal nerves of cattle resemble those of the horse in their origins and general arrangement. Arnold and Kitchell (1957), while studying the Th₁₁, Th₁₂ and Th₁₃ nerves, state that the medial branches of the dorsal branches

of these nerves do not terminate as cutaneous branches; while their lateral branches are very unique in their course and, before emerging from lumbodorsal fascia, again subdivide into two cutaneous branches - one larger than the other. The larger branch innervates the dorsal part; while the smaller branch traverses to ramify in the skin about the level of the tuber coxae.

In the case of the dog, Sussdorf (1889); Dusser de Barenne (1911); and Bernhard (1962), have done work on the innervation of the skin. Miller, et al. (1964) describe in detail the innervation of the skin of the thoracic region. The spinal nerves divide into dorsal and ventral branches and again the dorsal root divides into medial and lateral branches. The medial branches do not end in cutaneous branches and the innervation of the dorsolateral aspect of the thoracic region is mainly by the dorsolateral branches. A typical intercostal nerve gives off five branches in all; a visceral branch, the proximal muscular branch, the distal lateral cutaneous branch, the distal muscular branch and the ventral cutaneous branch. The innervation of the skin of the lateral thoracic wall and the ventral thoracic region is by means of the distal lateral cutaneous branches and the ventral cutaneous branches. Others do not give any branch to the skin.

In the case of the cat, most of the work on the innervation of the skin has been done by the electrical resistance method of Kuhn (1953) and Hekmatpanah (1961). The authors state that the tactile dermatomes of the T₂ to T₁₃ nerves innervate the skin of the thoracic region.

In man, Davies, Gladstone and Stibbe (1932), traced the ventral root of the thoracic nerves. He found that in man, the intercostal nerve gives off three main cutaneous branches for the innervation of the skin of the thoracic region. The main nerve continues as the anterior cutaneous branch, giving off a lateral cutaneous branch and one collateral branch which either rejoins the anterior cutaneous nerve or innervates the skin as the second anterior cutaneous branch. In man, the lower intercostal nerves form an elaborate plexus in the abdominal wall. Each muscle and the skin of this region receive branches from at least two, and more commonly three, spinal nerves.

Sinclair (1937) writes that the pattern of innervation in the pig is exactly the same as that in man. He goes to the extent of dividing the body into segments similar to that of man. There is no independent description available as far as the cutaneous branches are concerned, but the innervation in the pig, in general, can be said to be of the following pattern according to Sinclair:

- 1) Caudal to the jaw all deep muscles are innervated by nerves of the segments in which they lie.
- 2) All superficial muscles have innervation from nerves cranial to them and the most superficial from the most distant nerve origins.
- 3) Epiaxial muscles are innervated by the dorsal or the epiaxial rami of the spinal nerves.
- 4) The limb muscles are innervated by lateral divisions of the lateral or hypaxial rami.

The distribution of the root fibers retains the original segmental order on the surface of the skin and on the muscles in both limbs and trunk. Sisson and Grossman (1953) state that there are commonly fourteen pairs of thoracic spinal nerves while Montañe and Bourdelle (1920) state that the pig has fourteen to fifteen pairs of thoracic spinal nerves, which divide into superior and inferior branches. The superior branches terminate in the dorsal spinal muscles while the inferior branches traverse ventrally and give off perforating branches. The major portion of the first thoracic nerve (inferior branch) is a contribution to the formation of the brachial plexus. Jankovic (1954) describes fourteen pairs of thoracic spinal nerves and states that the number is variable.

C. Lumbar Cutaneous Nerves

The lumbar region of all the domesticated animals is innervated by the lumbar spinal nerves. The number of these nerves varies from species to species. According to Seiferle (1939), and confirmed by a number of other workers, there are six lumbar nerves in the case of the horse and cattle. In the case of the dog there are seven pairs (Thiel, 1941). In sheep there are six pairs of lumbar nerves (Goller, 1959) and in the pig the number of spinal lumbar nerves is five to seven pairs, but usually there are seven pairs, according to Jankovic (1954) and Reimers (1913). However, Uchida (1929) found six pairs of lumbar sympathetic ganglion in all the specimens, which were equated with the lumbar vertebrae present. These nerves have all the characteristic features of a typical spinal nerve. In the earlier investigations the different branches of the dorsal and ventral roots of a particular spinal nerve were given different names, as has been done by Reimers (1913); Bolk (1898-1899); Sisson and Grossman (1953); and Arnold and Kitchell (1957); thus, there exists a great deal of confusion regarding the nomenclature of the various ventral branches of the lumbar spinal nerves.

According to Barone (1964) and Sisson and Grossman (1953) the lumbar spinal nerves divide into dorsal and ventral branches.

The dorsal branches further subdivide into medial and lateral branches. The medial branches constitute the innervation of the lumbar spinal muscles while the lateral branches terminate as cutaneous branches. The ventral branches of the first three lumbar spinal nerves are called the iliohypogastric, ilioinguinal and genitofemoral or external spermatic nerves. The first two are said to divide into deep and superficial branches. The superficial, or cutaneous branches, according to Sisson and Grossman (1953) ramify in the skin of the crural region of the flank and thigh, while the ventral superficial branch of the third lumbar spinal nerve constitutes the lateral femero-cutaneous nerve. According to Barone (1964), the lateral femero-cutaneous nerve is reinforced by a branch from the fourth lumbar nerve at its origin. The ventral branches of the fourth, fifth and sixth lumbar spinal nerves contribute to the formation of the lumbosacral plexus.

In the case of cattle, Reimers (1913) has described the ventral rami of the various lumbar nerves as not dividing into ventrolateral and ventromedial branches. The main innervation of the lumbar region is from the branches given off by the first, second, and third lumbar nerves while the fourth, fifth, and sixth lumbar nerves give off cutaneous branches for the innervation of the external genitalia of the male or female

and for the innervation of the thigh, etc. In the first, second, and third lumbar nerves ventral rami have been described as giving off branches called the iliohypogastric, ilioinguinal and muscular rami, etc. Walter (1959) and Arnold and Kitchell (1957) have described the lumbar nerves as being divided into dorsomedial, dorsolateral, ventromedial and ventrolateral branches. Dorsomedial branches are responsible for the innervation of the muscles of this region and do not give any cutaneous branches. The dorsolateral branches continue ventrally and further divide into large and small nerves which ultimately pierce through the obliquus abdominis externus muscle and innervate the skin at the level of the tuber coxae.

The ventral branches divide into ventromedial and ventrolateral branches. The ventrolateral branches of the lumbar nerves traverse through the transverse abdominis and external abdominal oblique muscles, finally piercing through the musculature to innervate the skin. The ventrolateral branch of the second lumbar innervates the lateral abdominal wall, the third lumbar gives fibers to the lateral cutaneous nerve of the thigh and the fourth lumbar nerve passes in a posterior direction and then gives some fibers to the lateral cutaneous nerves. Arnold and Kitchell (1957) describe that sometimes as many as three spinal nerves may be responsible for the innervation of

a given area of skin indicating that perhaps in this region there is a segmental pattern of innervation, but in addition there is an overlapping.

In the dog, there are seven lumbar nerves, as stated previously. These have been described by various workers in the field of anatomy and others studying the lumbar block. The latest information available is according to Miller et al. (1964). The dorsomedial branches do not usually give off branches for the innervation of the skin. Occasionally one branch may be given for the innervation. However, dorsolateral branches of the first three or four lumbar nerves run caudo-ventrally and pierce through the lumbodorsal fascia to arborize in the skin of the dorsolateral parts of the lumbar and sacral regions as the dorsal cutaneous branches. Cutaneous branches of the lateral branches of the dorsal ramus are usually variable. Occasionally, all the lumbar nerves have these branches. In other cases, it was seen that a single dorsal branch bifurcates deeply in the epaxial musculature, resulting in two cutaneous branches which supply the skin of either side of the dorsum. In some, the dorsal cutaneous branch of either the fifth, sixth, or seventh lumbar nerve innervates the skin adjacent to it as well as much of that lying over the rump. In the last three or four lumbar nerves, there is no clear cut division of dorsal branches into dorsomedial and dorsolateral

branches. The ventral branches of the first two lumbar nerves divide into medial and lateral branches. The last five lumbar nerves go into the formation of the lumbosacral plexus. The lateral branch gives off lateral cutaneous nerves which innervate the ventrolateral part of the abdomen caudal to the ribs. The medial branches give off cutaneous branches which supply the skin of the area of the rectus abdominis muscle. Other lumbar nerves give off cutaneous branches for the innervation of the thigh and hind limb. In the case of the pig the number of lumbar vertebrae is variable, from five to seven. Commonly, there are seven lumbar vertebrae and seven lumbar nerves but the number of nerves varies according to the number of lumbar vertebrae. According to Reimers (1913) the branching of the various lumbar nerves is as follows:

- 1) The N. iliohypogastricus accessorius or L₁ has almost the same course in the pig as that of cattle. It divides into two branches, ramus superficialis and ramus profundus. These nerves do not communicate with the corresponding branches of the following nerves and the ramus superficialis passes undivided to the skin of the region - iliaca. The ramus profundus proceeds a short distance between the peritoneum and the M. obliquus abdominis internus, then obliquely pierces the transverse abdominis and obliquus abdominis externus muscle to

extend below the skin of the lateral abdominal wall and spreads in the skin of the regio iliaca, the knee fold and the thigh, This nerve arises from the ramus ventralis of the first lumbar nerve. In pigs with only six lumbar vertebrae it is present as the supranumerary intercostal nerve.

2) The N. iliohypogastricus arises from the R.v. of the second lumbar nerve and corresponds to the similarly designated nerve of cattle. It proceeds parallel to the former nerve and likewise divides into the ramus superficialis and ramus profundus, which ramify in the same area caudal to the corresponding branches of the first lumbar nerve.

3) The N. ilioinguinalis arises from the ramus ventralis of the third lumbar nerve, usually in common with the ramus muscularis for the M. obliquus abdominis internus. Sometimes it receives a ramifying branch from the L₂ nerve. It also divides into the ramus superficialis and ramus profundus. The ramus superficialis proceeds like the corresponding branch of the N. iliohypogastricus and parallel with it, gives off twigs to the Mm. transversus abdominis and obliquus abdominis externus, enters the lateral abdominal wall superficially after piercing the muscles and ramifies in the skin of the regio iliaca and of the lateral surface of the thigh caudal to the ramus superficialis of the N. iliohypogastricus. The ramus profundus innervates the scrotum or prepuce in males and the udder in females.

4) The ramus muscularis for the M. obliquus abdominis internus arises in common with the former L₃ nerve or occasionally from the ramus profundus of the N. ilioinguinalis. Sometimes it receives a supporting branch from the R.v. of the L₄ nerve. It is distributed in the M. obliquus abdominis internus.

5) The N. spermaticus externus arises from the ramus ventralis of the L₄ nerve and derives from only one trunk. It proceeds in a caudoventral direction and ultimately ramifies in the prepuce, scrotum, cremaster muscle, and tunica vaginalis communis of the testicle and of the spermatic cord, or else in the udder.

6) The N. cutaneus femoris lateralis arises from the ramus ventralis of the L₅ nerve. Sometimes near its origin it receives a supporting branch from the R.v. of the L₆ nerve and it innervates the skin of the thigh.

7) The N. femoralis arises from the ramus ventralis of the L₆ nerve in common with the N. obturatorius. It does not give any branch for the innervation of the skin.

8) The N. obturatorius arises in common with the N. femoralis from the L₆ nerve. It gets a slender reinforcing branch from the L₇ nerve. It does not innervate the skin.

9) The L₇ nerve maintains a relationship as in cattle and in the pelvic cavity gives off one or two slender branches to the M. obturator internus.

Montané and Bourdelle (1920) state that there are six to seven pairs of lumbar spinal nerves in the pig, which divide into superior and inferior branches. The superior branches terminate in the muscles of the lumbar spinal region and the inferior branches are different from each other depending upon the pair considered. The first two or three distribute themselves in the abdominal wall, the fourth and fifth furnish a branch to the N. cutaneous femoris lateralis and also gives a contributory branch for the formation of the lumbosacral plexus. The inferior branches of the last two lumbar spinal nerves go completely in the formation of the lumbosacral plexus.

D. Sacral Cutaneous Nerves

According to Barone (1964); Sisson and Grossman (1953); Chaveau and Arloing (1902); and Ellenberger and Baum (1943); there are five pairs of sacral spinal nerves in the horse and these further divide into dorsal and ventral sacral nerves. The innervation of the skin of the croup region is mainly constituted by the lateral branches of the dorsal branches; while their medial branches are distributed to the muscles lying over the sacral spines and the proximal part of the tail. The cutaneous branches of the first sacral spinal nerve are relatively long and the dorsal branch of the last sacral spinal

nerve anastomoses with the dorsal branch of the first coccygeal spinal nerve to help in the formation of the dorsal coccygeal trunk. The ventral branches emerge through the ventral sacral foramen except the last one which passes through the intervertebral foramen between the last sacral segment and the first coccygeal vertebra. The first two go entirely in the formation of the lumbosacral plexus. The ventral branch of the last sacral nerve contributes to the ventral branch of the first coccygeal nerve.

Similarly, in the case of cattle, according to Reimers (1913); Schaller (1956); and Sisson and Grossman (1953); there are five pairs of sacral spinal nerves. Schaller (1956) describes the innervation of the region of the rump by the dorsal branches of the sacral spinal nerves. He found that the size of these cutaneous branches of the dorsal branches decreases comparatively from the first to the last. The dorsal branch of the last sacral spinal nerve contributes to the dorsal branch of the first coccygeal spinal nerve to form the dorsal coccygeal trunk as in the horse. Reimers (1913) described the ventral branches of the sacral spinal nerves as similar to that of the horse in origin and arrangement.

According to Miller et al. (1964), in the dog the three sacral nerves leave the three sacral segments of the spinal

cord by large dorsal and ventral roots which respectively emerge through the dorsal sacral and ventral sacral foramina. The dorsal branches are united to each other by communicating branches and form a dorsal sacral trunk or plexus and is usually joined to the dorsal branches of the last lumbar and first coccygeal nerves. These divide into medial and lateral branches. The medial branches are very small and supply the musculature. The lateral branches are longer and traverse ventrodorsolaterally. According to Reimers (1913), the first sacral nerve divides while traversing through the gluteal fascia and these are the two cutaneous branches which innervate the skin of the thigh. The second and third sacral nerves divide and innervate in the same way and these three cutaneous nerves have been referred to as middle clunial nerves by Ellenberger and Baum (1943). In the pig, according to Reimers (1913); Montane and Bourdelle (1920); Sisson and Grossman (1953); and Jan-kovic (1954) there are four pairs of sacral spinal nerves which divide into dorsal and ventral branches as soon as these emerge through the intervertebral foramin as in the horse. This dorsal branches are mainly responsible for the innervation of the skin of the rump region while, according to Reimers (1913), the distribution of the ventral branches is as follows:

1) N. sacralis I connects its whole bulk of fibers with the L₇ nerve and the N. sacralis II to form the ischiatic plexus.

2) N. sacralis II - ramus ventralis is more slender than the S₁, usually it gives off a loop to the R.v. of S₃. It joins the L₇ nerve and S₁ nerve ventral to the second ventral sacral foramen and leads into the formation of the plexus ischiadicus. From it arises the N. gluteus cranialis, rami muscularis, N. ischiadicus, N. gluteus caudalis and N. cutaneus femoris caudalis. The N. cutaneus femoris caudalis arises from the ischiatic plexus almost immediately after the N. gluteus caudalis, seldom before it. Then it proceeds medial to the ligamentum sacrospinosum et tuberosum in a caudoventral direction to the tuber ischii and passes here to the superficial surface, in order to innervate the skin of the area of the muscles of the buttock.

3) The ramus ventralis of S₃ is more slender than the preceding nerve and gives rise to the N. pudendus and N. hemorrhoidalis medius. The N. pudendus arises from the ramus ventralis S₃ nerve in common with the N. hemorrhoidalis medius, proceeds to the ischial arch and innervates the male or female genitalia. It splits into one or more cutaneous branches in the pelvic cavity which, after dividing, supply the skin in

the region of the buttock muscles. In pigs, one can further distinguish a ramus cutaneus proximalis and distalis as well as, at times, a ramus cutaneus medius. The N. hemorrhoidalis medius arises in common with the N. pudendus from the R.v. S₄ nerve and traverses caudoventrally and, before ramifying in the M. levator ani, it gives off a cutaneous branch known as the N. perinei which innervates the skin of the perineal region.

E. Coccygeal Cutaneous Nerves

The number of coccygeal nerves varies from animal to animal. The coccygeal vertebrae are quite large in number but mostly there are four to five pairs of coccygeal nerves in the domesticated animals. The coccygeal nerves, after emerging, divide into dorsal and ventral branches. The dorsal roots of the coccygeal nerves unite and lead into the formation of the dorsal nerve trunk and similarly the ventral roots unite and lead to the formation of the ventral nerve trunk. The ventral nerve trunk is larger than the dorsal.

In the case of the horse, according to Sisson and Grossman (1953) there are five pairs of coccygeal nerves which, like a typical spinal nerve, divide into dorsal and ventral roots leading into the formation of dorsal and ventral nerve trunks

which traverse to the tip of the tail. The dorsal nerve trunk is smaller than the ventral nerve trunk and gives very few cutaneous branches. The main innervation of the skin of the tail is from the ventral nerve trunk. Barone (1964) states that there are commonly five pairs, but sometimes six pairs, of coccygeal spinal nerves.

The pattern of innervation of the tail is similar in cattle to that of the horse. But Schaller (1956), found up to seven pairs of coccygeal spinal nerves which divide into dorsal and ventral branches as in the horse.

In the dog, Havelka (1928) described four to seven pairs of coccygeal nerves, which was earlier reported by Ellenberger and Baum (1891). Hopkins (1935) found five pairs of coccygeal nerves in each of the nine mongrel dogs dissected. Like other typical spinal nerves, these also divided into dorsal and ventral branches forming dorsal and ventral nerve trunks. Baum and Zietzschmann (1936) named these trunks the N. collector caudalis dorsalis and the N. collector caudalis ventralis, respectively. Some workers have also called them plexuses. The dorsal trunk lies directly on the transverse processes and intertransversarii muscles. Miller et al. (1964) state that only two branches which innervate the skin could be traced.

The ventral nerve trunk is larger than the dorsal nerve trunk. It is covered ventrally by the ventral sacrococcygeal

muscle and it extends to the tip of the tail. It gives branches to the ventral sacrococcygeus muscles and the first seven to nine branches end in discernible cutaneous branches which innervate the skin of the tail.

In the case of the pig, there is not much known about the coccygeal nerves as most of the books on comparative anatomy do not give the number of coccygeal spinal nerves. However, Montañe and Bourdelle (1920) state that there are six to seven pairs of coccygeal spinal nerves in the pig; while Jankovic (1954) states that there are only two or three pairs of coccygeal spinal nerves though the number is highly variable.

III. MATERIALS AND METHODS

Eleven pigs, seven females and four males, of varying breeds and ages were dissected.

Most of the specimens were prepared and embalmed by the usual embalming technique followed in the Department of Veterinary Anatomy at Iowa State University, except for two pigs which were dissected in the fresh state. The animals to be embalmed were first anesthetized with pentobarbital sodium and then bled (in some cases by cannulating the carotid artery and in other by cannulating the femoral artery). In this manner, if some cutaneous twigs were lost due to the incision made to cannulate the carotid artery they could be traced in the specimens bled by cannulating the femoral artery. These specimens were then infused with the embalming fluid consisting of the following ingredients in the ratios given:

Isopropyl alcohol	60 percent
Formaldehyde	4 percent
Liquid phenol	6 percent
Corn syrup	2.5 percent (50 percent water)
Water	27.5 percent

After embalming and throughout the investigations, the specimens were kept in the cooler.

The fresh specimens, obtained from the Department of Biomedical Electronics, were electrocuted and then bled immediately. These specimens were kept in the cold storage and provided good material for dissecting the thoracic region, especially the termination of the intercostal nerves as ventral cutaneous branches, by the medial approach. These were kept in the cooler, but, after some time had to be discarded.

Essentially two methods of approach -- centripetal and centrifugal -- were followed, for dissecting the various cutaneous nerves. In the first method the nerves were picked up on the surface of the skin and were then traced back to their point of origin. In the second method, the nerves were followed from their point of origin to their termination on the surface of the skin. Some specimens were dissected using the medial approach to study the course and termination of the intercostal nerves. In one specimen, the skin was completely removed and the cutaneous nerves of the different regions were picked up and cleaned in order to study them in relation to the superficial muscles of the body.

In the first method, the dissection was initiated in the cervical region by a mid-dorsal incision from the skull to the seventh cervical vertebra and then two straight ventral incisions were made at these levels. The skin was then gently

reflected in a ventral direction. During the process various cutaneous branches were picked up and subsequently traced to their origin in order to ascertain the branch and number of the cervical nerve which gave off the particular cutaneous branch. In most of the cases the cutaneous branches were tagged with a particular number to make sure that they were not mixed up at the deeper stages of dissection. The course and direction in which these branches traversed and the various muscles through which they passed, or to which they had some relation during their course, were observed and recorded. The cutaneous branches of the thoracic, lumbar, sacral and coccygeal regions were traced in a similar manner by using an appropriate dorsal and then ventral incision. For the dissection of the thoracic and lumbar regions first a straight 8 inch ventral incision was made at the level of the seventh cervical vertebra and tuber coxae, respectively, to reflect the skin. Next, a horizontal incision was made nearly 2 inches below the level at which the first series of cutaneous branches of the thoracic and lumbar spinal nerves were picked up. The cutaneous innervation of the whole thoracic and lumbar region was investigated using this approach, as it enabled one to very effectively study the innervation of various segments of these regions in relation to the series

of nerves given off at different levels. This method was very useful and effective except for the dorsomedial branches of the spinal nerves, which emerge on the surface of the skin almost at the mid-dorsal line. Therefore, to study these nerves the second method of investigation was followed and these nerves were traced from their origin at the level of the intervertebral foramen to their termination at the mid-dorsal line. Similarly, to study the ramification of the intercostal nerves as the ventral cutaneous branches, a medial approach of dissection was followed.

The cutaneous branches of the sacral spinal nerves were investigated using the first method. For studying the cutaneous branches of the coccygeal spinal nerves, the portion from the sacrum of the tail was removed from the body along with the muscles, skin and the vertebral column. The investigations were then carried on as usual. This approach was necessary due to the fact that the ventral branches of the coccygeal spinal nerves could not be dissected effectively in situ.

At times the nerves were painted with yellow latex and then photographed for the purpose of illustration as referred to in the Results and Discussion. Moreover, a few drawings of the different regions were also made and these, as well, have been incorporated to clarify the points which could not be illustrated by the photographs.

IV. RESULTS

A. Cervical Cutaneous Nerves (Nn. Cutanei Cervicales)

The innervation of the skin of the neck region was from the cutaneous branches gives off by the cervical nerves (Nn. cervicales). All of the ten specimens dissected had eight pairs of cervical nerves, although there were seven cervical vertebrae. Therefore, unlike all other spinal nerves (Nn. spinales), the cervical nerves lay cranial to the cervical vertebra with the corresponding number, except for the first and last cervical nerve. The first cervical nerve was found to emerge through the lateral vertebral foramen of the atlas while the eighth cervical nerve emerged through the intervertebral foramen between the last cervical and first thoracic vertebrae, lying cranial to the first thoracic vertebra. Other than number, each cervical nerve had all the characteristics of a typical spinal nerve and soon after its emergence divided into two branches, dorsal and ventral. The dorsal branches were much thinner than the ventral branches and extended dorsally while the larger, stronger and well-developed ventral branches traversed caudoventrally. Both dorsal and ventral branches subdivided and gave off some branches which terminated as cutaneous branches to innervate the skin of the neck region. The manner of origin,

course, branching, distribution, relationship, and the area of ramification was quite variable from specimen to specimen and sometimes there were minor differences in relationships and branching of these nerves in the right and left sides of the same specimen. But even then, most of the dissected specimens showed almost the same pattern with little variation. These variations were more marked in the ventral branches than in the dorsal branches of the cervical nerves.

1. Dorsal Branches (Rami dorsales)

The dorsal branches which were much thinner and finer than the ventral branches (Rami ventrales) of the cervical nerves, further subdivided into medial (Rami mediales) and lateral (Rami laterales) branches. The medial branches were much larger than the lateral branches, though this subdivision of the dorsal branches was not always marked and distinct. In four cases no distinct subdivision was observed, though in all these cases the dorsal branches gave off well-developed and distinct muscular branches, comparable to the lateral branches for the innervation of the muscles of the neck region. In their dorsal course to reach the surface of the skin these finally terminated as the cutaneous branches. In all the specimens dissected, it was observed that only the medial branches of the dorsal branches reached the surface of the skin of the

dorsolateral aspect of the neck region. The lateral branches were mainly responsible for the innervation of the various muscles of the neck region and did not appear on the surface of the skin. These branches were completely embedded in the various muscles of the neck and fascia in their entire course.

a. Dorsal branch of the first cervical nerve (Ramus dorsalis N. cervicalis primus (N. occipitalis)). As the first cervical nerve emerged through the lateral vertebral foramen of the atlas it gave off a dorsal and a ventral branch as stated earlier. The dorsal branch had a craniodorsal ascending course and lay between the M. obliquus capitis caudalis and M. rectus capitis dorsalis major. It continued in its dorsal course going deep into the muscles of the cranial part of the neck and lay under cover of the M. semispinalis capitis and M. spenius to spread out finally in the M. rectus capitis dorsalis major and supraspinous ligament (Ligamentum nuchae). The dorsal branch of the first cervical nerve did not divide into medial and lateral branches in any of the specimens, though it gave off distinct branches for the innervation of the muscles of the neck during its course and ascended dorsally to the mid-dorsal line. In all specimens dissected, except for two cases, it did not penetrate through the musculature to terminate as cutaneous branches. In the case where it did perforate through it was distributed to the skin covering the base of the pinna just caudal to the poll.

b. Dorsal branch of the second cervical nerve (Ramus dorsalis N. cervicalis secundus) Soon after its emergence through the intervertebral foramen between the atlas and the axis vertebrae, the dorsal branch coursed a very short distance caudally and then ascended in a caudodorsal direction between the M. obliquus capitis caudalis and M. intertransversarius dorsalis. It transversed a short distance under cover of these muscles and then passed through the M. semispinalis capitis and M. splenius. It divided into medial and lateral branches. The smaller lateral branches were distributed in the muscles of the neck while the slender, large medial branches continued to ascend towards the spine of the axis and finally perforated the M. rhomboideus cervicis, M. trapezius (Pars cervicalis) and the ligamentum nuchae to appear on the under surface of the skin of the mid-dorsal aspect of the neck. (Fig. No. L₁, 5: C₂a') On the surface of the neck this medial, cutaneous branch usually bent craniolaterally and spread out on the surface of the skin covering the base of the pinna and caudal part of the temporal muscles. Those cases where the dorsal branch of the first cervical nerve terminated as a cutaneous branch, it seems that its area of ramification was seen lying just cranial to the dorsal branch of the second cervical nerve.

c. Dorsal branches of cervical nerves III to VII
 (Rami dorsales Nn. cervicales tertius to septimus) The
 course followed by the dorsal branches of the third to
 seventh cervical nerves was almost the same, though there
 were a few variations. These dorsal branches were of al-
 most equal size, though it appeared that the dorsal branch
 of the second or third was much larger as compared with the
 dorsal branch of the seventh cervical nerve (Fig. No. 4).

Immediately after their emergence through the lateral
 vertebral foramen, the dorsal branches followed a caudo-
 dorsal, usually dorsal, course between the M. multifidus
 cervicis and M. longissimus capitis et atlantis. After
 traversing a short distance, these branches divided into
 medial and lateral branches. The lateral branches went
 into the musculature of the neck, usually spreading out
 on the M. complexus and M. biventer (Cervicis). The slen-
 der medial branches continued ascending dorsally, passing
 through the M. semispinalis capitis and M. splenius to-
 wards the mid-dorsal line. (Fig. No. 4: C₂a' - C₇a').
 Ultimately, these branches perforated the M. splenius and
 M. semispinalis capitis to reach between the M. semispinalis
 capitis and the lamellar part of the ligamentum nuchae (Fig.
 No. 5: C₂a'). Finally, the medial branches pierced the M.
 rhomboideus cervicis, M. trapezius (Pars cervicalis) and
 supraspinous ligament to appear on the surface of the skin.

These branches have been found to have communicating branches with each other, except for the dorsal branches of the second, third, seventh, and eighth cervical nerves. (Fig. No. 4 and 5). In most of the cases it was seen that the fourth, fifth and sixth cervical nerves gave off communicating branches to each other. In only two out of eleven specimens dissected there were no such communicating branches. It was observed that these branches bent laterally and traversed a very short distance before spreading out on the surface of the skin. But, it has been noted that the medial branches of the dorsal branch of the third or fourth cervical nerve traversed a considerable distance under the skin and were embedded in the superficial fat going as far as the middle of the neck region.

The dorsal branch of the eighth cervical nerve (N. cervicalis VIII) was very small and did not terminate as a cutaneous branch. There was no distinct division into medial and lateral branches and in none of the specimens dissected could this branch be traced to the surface of the skin. It appeared grossly as terminating in the muscles of this region.

2. Ventral branches of the cervical nerves I - VIII (Rami ventralis Mn. cervicales primus to octavus)

The larger ventral branches showed a lot of variation in their branching and arrangement and were given off at different

levels. Soon after their exit from the vertebral canal through the intervertebral foramen between the preceding and the cervical vertebrae with the corresponding number they divided into two unequal branches, medial and lateral. The medial branches (Rami mediales) were smaller and took an oblique dorsal course and were responsible for the innervation of the musculature of the neck. The larger and stronger lateral branches (Rami laterales) transversed caudoventrally and usually further subdivided into two or more branches. It has been observed that the lateral branches in most of the cases gave off strong communicating branches (Rami communicantes) which resulted in the formation of the ventral cervical plexus (Plexus cervicalis ventralis). In the eleven specimens dissected, there were three main types of communicating arrangements between these branches, though minor variations existed in each one. It has also been observed that variations existed in their arrangement in the same animal on the left and right sides. However, in spite of all these variations, there was a fairly constant manner of their branching, distribution and area of ramification.

Type I - In seven cases, the lateral branch of the second ventral cervical nerve united with the third and there was communication between the lateral branches (Rami laterales) of the fourth and fifth ventral

branches. The fifth, sixth, seventh and eighth nerves united with each other. In five cases out of seven, it was observed that the lateral branch of the fifth ventral branch gave off a branch which united with the lateral branch of the fourth ventral branch, while in two cases the lateral branch of the fourth united with the lateral branch of the fifth (Fig. No. 2, 3, 4, 5; Plate No. 1, 2: $C_2b'' - C_8b''$).

- Type II - In two cases, it was observed that the lateral branches of the second and third ventral cervical nerves united with each other, while lateral branches of the fourth and fifth did not have any communicating branches with each other. The fifth, sixth, seventh, and eighth had communicating branches (Rami communicantes) (Plate No. 3).
- Type III - In one case, it was observed that all the lateral branches of the cervical nerves, except that of the first, united with each other (Plate No. 4.)

These are the principal patterns of branching found in the case of the cervical nerves. So, it has been observed that the formation of the ventral cervical plexus was not a constant feature in the case of the pig. In only one specimen was a communicating branch found between the lateral branches of the third and fourth ventral branches of the cervical nerves.

a. Ventral branch of the first cervical nerve (Ramus ventralis N. cervicalis primus) The ventral branch of the first cervical nerve was comparatively smaller than the ventral branches of the preceding cervical spinal nerves. It traversed caudolaterally under the wing of the atlas, along with the occipital artery (A. occipitalis) and vein lying between the M. rectus capitis lateralis and M. rectus capitis ventralis major (Fig. No. 5; Plate No. 4). It usually divided into two branches and then went deep to lie along with the vagosymphathetic trunk (Truncus vagosymphatheticus), finally spreading out in the deep muscles of the neck. It did not give off any cutaneous branches for the innervation of the skin.

b. Ventral branch of the second cervical nerve (Ramus ventralis N. cervicalis secundus) The ventral branch of the second cervical nerve was stronger than its dorsal branch. Soon after its emergence from the spinal canal, lying along the axis vertebrae, it traversed slightly caudally. The major portion of this nerve then united with the ventral branch of the third cervical nerve. Usually, before this union it gave off a small branch, which coursed towards the jugular furrow and was distributed in the muscles of the neck (Fig. No. 2, 3, 4, 5; Plate No. 1, 2, 3, 4: C₂b and C₂b").

From this trunk, formed by the union of the ventral branches of the second and third cervical nerves, a branch, corresponding to the great auricular nerve of the other domestic animals, was given off. It was observed that the ventral branch of the second cervical nerve did not have an independent course, as was the case in the other domestic animals and, therefore, the great auricular as well as the transverse cervical nerves were given off by the joined trunk. (Fig. No. 2, 3, 4, 5: A).

The great auricular nerve (N. auricularis magnus) was very well developed. It had a craniodorsal course and was covered by the M. brachiocephalicus and M. serratus ventralis cervicis, lying over the M. splenius. At this level, it further subdivided into two branches, cranial and caudal. The larger cranial branch continued craniodorsally in the direction of the pinna, while the smaller caudal branch stretched caudally to ramify in the muscles of this region. The larger cranial branch ascended toward the base of the ear and finally emerged from the M. cleido-occipitalis to spread out on the skin around the apex of the ear. Before its ramification in the skin it usually divided into two or three very distinct cutaneous branches, which were responsible for the innervation of the skin of this region. (Fig. No. 1: C₂ + 3b").

The smaller transverse cervical nerve (N. transversus cervicalis) traversed caudoventrally, crossing over the jugular vein and, in some cases, dividing into two branches at this level. One of these branches traversed cranially towards the parotid salivary gland, while the main branch continued caudally towards the ventral aspect of the neck. It was observed that at this point it also received contributory twigs from the spinal accessory nerve (N. spinalis accessorius). (Plate No. 1, 2). After reaching the ventral aspect, it emerged through the cutaneous muscle and ramified in the skin of this region. (Fig. No. 3, 4, 5; Plate No. 3).

c. Ventral branch of the third cervical nerve (Ramus ventralis N. cervicalis tertius) Soon after its emergence through the intervertebral foramen between the second and third cervical vertebrae the well-developed ventral branch of the third cervical nerve was joined by the ventral branch of the second cervical nerve. After traversing a short distance, it divided into two branches. The smaller medial branch taking a craniodorsal course, initially lay between the M. brachiocephalicus, M. serratus ventralis cervicis and M. splenius. It ultimately ramified in the muscles of the neck region and did not give off any cutaneous branches. (Fig. No. 3, 4, 5; Plate No. 1, 3: C₃b'). The larger lateral branch traversed ventrally, lying over the M. rectus capitis

ventralis major and, after a short distance, divided into two well-developed cranial and caudal branches. The ventrolateral branch, from the second cervical nerve, usually joined with it. It then continued as the transverse cervical nerve. The main part of the ventral branch of the third cervical nerve itself continued to traverse ventrally and further subdivided into two or three branches. Usually, at this level, it was observed that the dorsal branch of the spinal accessory nerve (Ramus dorsalis N. accessorius) gave off contributory branches to this branch (Plate No. 1, 2: XI).

The cranial branch coursed towards the ventral part of the parotid salivary gland and usually was distributed over the skin of this region. The caudal branch had a caudoventral course, lying between the M. brachiocephalicus and the M. omotransversarius, passing ventrolaterally and finally spreading out on the skin of the middle part of the ventrolateral aspect of the neck (Fig. No. 1: C₂ + 3b").

In one case, on the right side only, there was a branch given off by the caudal branch of the ventrolateral branch of the third cervical nerve, which united with the ventral branch of the fourth cervical nerve (Plate No. 4: C₄b"). Except for one case, no such communication between the third and fourth cervical nerves was observed.

d. Ventral branch of the fourth cervical nerve (Ramus ventralis N. cervicalis quartus) The ventral branch of the fourth cervical nerve was more well-developed than the preceding nerve. It also divided into medial and lateral branches after its exit from the intervertebral foramen between the third and fourth cervical vertebrae. The smaller medial branch had almost the same course as that of the corresponding branch of the third cervical nerve and was finally distributed in the musculature of this region. The larger lateral branch passed over the M. scalenus ventralis in a caudoventral direction under the M. brachiocephalicus and M. omotransversarius. After traversing a considerable distance, it usually received a communicating branch from the ventral branch of the fifth cervical nerve (Fig. No. 2, 3, 4, 5; Plate No. 1, 2, 4: C₅b"). This was a common and constant feature in all the specimens dissected, though there were some variations as to the manner in which this union took place. In two cases, the ventral branch of the fourth cervical nerve gave off a communicating branch to the ventral branch of the fifth cervical nerve. In two cases, though the ventral branch of the fifth gave off a communicating branch to the ventral branch of the fourth cervical nerve, this union occurred after it further subdivided into cranial and caudal branches. In all the rest of the cases the fifth united with

the ventral branch of the fourth before its subdivision. In two cases on the left side, it was observed that no communicating branches existed between the ventral branches of the fourth and fifth cervical nerves (Plate No. 3). However, under the M. brachiocephalicus just cranial to the shoulder joint it divided into cranial and caudal branches which ultimately emerged from the M. brachiocephalicus and traversed superficially under the skin towards the ventral aspect of the neck (Fig. No. 1: $C_4 + 5^b$). It separated into a number of small cutaneous branches which spread out on the surface of the skin of the ventral aspect of the neck cranial to the sternum. In cases where the ventral branch of the fourth cervical nerve united with the ventral branch of the fifth cervical nerve, it followed the same course as that of the corresponding branch of the fourth and ramified in the same area which is otherwise innervated by the caudal branch of the fourth cervical nerve. The cranial branch ramified in the skin of the same region as that of the caudal branch (Fig. No. 1: $C_4 + 5^b$).

The ventral branch of the fourth cervical nerve received a communicating branch from the ventral branch of the third cervical nerve in only one case.

e. Ventral branch of the fifth cervical nerve (Ramus ventralis N. cervicalis quintus) The ventral branch of the fifth cervical nerve initially lay under the M. scalenus dorsalis and divided into medial and lateral branches. The smaller medial branch passed under the M. scalenus dorsalis to ramify in the muscles of the neck. The larger lateral branch emerged between the M. scalenus dorsalis and the M. scalenus ventralis and immediately divided, in most cases, into two equal cranial and caudal branches. The cranial branch coursed cranioventrally over the M. scalenus ventralis to join with the caudal branch of the ventrolateral branch of the fourth cervical nerve (Fig. No. 2, 3, 4, 5, Plate No. 1, 2, 4: C₅b"). Then the conjoined trunk traversed caudo-laterally to reach the surface of the skin, as described earlier. The caudal branch traversed caudoventrally along the dorsal border of the M. scalenus ventralis and joined the ventral branch of the sixth cervical nerve (Ramus ventralis N. cervicalis sextus). In most of the cases, before uniting, it divided into two branches -- one joined with the ventral branch of the sixth cervical nerve while the other traversed under it and coursed towards the thoracic inlet.

In the cases where the cranial branch received a communicating branch from the ventrolateral branch of the fourth

cervical nerve it had been observed that the cranial branch took the place of the caudal branch of the ventrolateral branch of the fourth cervical nerve. It also had the same course and area of ramification as that of the branch it replaced and has been described previously.

In two cases, in which no communication between the ventral branches of the fourth and the fifth cervical nerves was observed the ventrolateral branch of the fifth cervical nerve subdivided into cranial and caudal branches as usual, but the cranial branch was very well-developed. (Plate No. 3; C₅b"). It passed over the N. scalenus ventralis and came to lie between the M. brachiocephalicus and N. omotransversarius. After traversing a considerable distance it further subdivided into two unequal branches. The smaller one traversed craniolaterally and ventrally towards the ventral aspect of the neck and finally arborized in the skin just caudal to the cutaneous branches of the fourth cervical nerve. The larger branches, after emerging through the M. brachiocephalicus, extended caudolaterally and ventrally traversed a considerable distance superficially under the skin to finally ramify in the skin of the ventral aspect of the neck adjacent to the sternum. (Fig. No. 1: C₄ + C₅b").

f. Ventral branches of cervical nerves sixth, seventh and eighth (Rami ventrales Nn. cervicales sextus, septimus, and octavus) These were very well-developed and strong branches initially lying under the M. scalenus dorsalis. These branches gave off small, medial branches which traversed caudodorsally while the bulk of the branches emerged between the M. scalenus dorsalis and M. scalenus ventralis. After a very short distance, the ventral branch of the sixth received a branch from the ventral branch of the fifth cervical nerve. This joined branch then united with the ventral branch of the seventh cervical nerve which, in turn, united with the ventral branch of the eighth cervical nerve, resulting in the formation of the brachial plexus (Plexus brachialis). (Fig. No. 2, 3, 4, 5, Plate No. 1, 2, 3, 4). The ventral branch of the eighth cervical nerve, in most cases, received the ventral branch of the first thoracic spinal nerve (Ramus ventralis N. spinalis thoracic).

Some branches which terminated as cutaneous branches on the skin of the ventrolateral aspect of the thoracic wall were from the conjoined branches of the eighth cervical and first thoracic spinal nerves, from which arose the lateral thoracic nerve, which traversed superficially, caudally and has been described separately. Besides this nerve, it has been found

that from the ventral branch of the eighth cervical nerve, at the middle of the cranial border of the first rib, a branch arose which traversed caudoventrolaterally under the medial aspect of the scapula and then emerged from the musculature at the ventral border of the M. latissimus dorsi to ramify in the fold of the skin dorsal to the olecranon process of the ulna (Fig. No. 1, 2, 8).

g. External or lateral thoracic nerve (N. thoracalis lateralis) In all the specimens dissected it was observed that the lateral thoracic nerve (N. thoracalis lateralis) arose from the brachial plexus (Plexus brachialis), its fibers mainly constituted by the ventral branches of the eighth cervical and first thoracic spinal nerve. It was given off just below the head of the first rib, then took a caudoventral course by the side of the first rib, lying under cover of the M. serratus ventralis thoracis (Fig. No. 2, 3, 4, 5, Plate No. 8: 11). After traversing a considerable distance at the level of fourth or fifth rib, it took a gradual turn to follow almost a straight caudal course to lie between the M. serratus ventralis thoracis and M. pectoralis profundus caudalis.

In its course it gave off a number of muscular and cutaneous branches which were responsible for the innervation of the various muscles of the ventrolateral aspect of the

thoracic and abdominal walls. The cutaneous branches were responsible for the innervation of the cranial ventrolateral aspect of the thoracic region, surrounding the mammary gland in the female and the retractor muscles of the penis and the skin of this region in the male. The main cutaneous branches were investigated and are described below.

At the level of the costochondral junction of the first rib, it gave off a long slender branch which traversed a short distance in conjunction with the brachial vein in a caudoventral direction and came to lie on the M. pectoralis profundus caudalis. It then took a caudal turn along with the vein and stretched in a dorsocaudal direction, crossing the lateral cutaneous branches of the second to fifth perforating branches of the intercostal nerves (Rami perforantes Nn. intercostales), and spread out as a cutaneous branch almost in the middle of the lateral thoracic wall at the level of the fifth to sixth rib (Fig. No. 2, 3, 4, 5, 8, 9, 10; Plate No. 8, 9, 10: 11).

The main trunk continued traversing caudoventrally and, during its course, gave off small twigs which, in some cases, joined the distal lateral cutaneous branches of the perforating branches of the intercostal nerves. These twigs usually joined with the distal lateral cutaneous branches of the third, fourth, fifth and sometimes the sixth perforating

branches. At the level of the eighth or ninth intercostal space, the lateral thoracic nerve emerged out of the M. pectoralis profundus caudalis and came to lie superficially under cover of the M. cutanei trunci. After a short distance it further subdivided into two branches, dorsal and ventral, in relation to the course followed by them.

The dorsal branch was a very fine, slender but long branch, which took a dorsocaudolateral course and was embedded in the M. cutanei trunci. During its course it gave off a number of small, fine twigs for the innervation of the skin of the ventrolateral aspect of the thoracic wall and the subcutaneous muscle. It was a very extensive branch and its fine fibers, ultimately, after reaching close to the plica, turned dorsally towards the flank region and finally spread out in the skin of this region.

The ventral branch was stronger than the dorsal branch and traversed caudoventrally, lying superficially under the skin. After a short distance it further subdivided into two branches, both of which gave off twigs which ramified in the skin around the penis and prepuce in the male. These branches finally spread out in the M. retractor penis. In the female, these branches gave off cutaneous branches ramifying in the skin above the mammary glands, except for the first pair, which was innervated by the ventral cutaneous branches of the eighth

or ninth intercostal nerves. The ventral branch finally was distributed in the penile muscles and the skin around the penis in the male (Fig. No. 12: Tb' and 11; Plate No. 9, 10: 11).

h. Phrenic nerve In all the specimens dissected it was observed that the phrenic nerve (N. phrenicus) was constituted by the branches from the ventral branches of the fifth and sixth cervical nerves (Rami ventralis Nn. spinalis cervicales V et VI). As described earlier, soon after its emergence the ventral branch of the fifth cervical nerve divided into medial and lateral branches. The medial branch took a dorsal course, while the lateral branch further subdivided into cranial and caudal branches. The cranial branch traversed cranioventrally to join the ventral branch of the fourth cervical nerve, while the caudal branch took a caudal course lying over the M. intransversarius ventralis. After a short distance it gave off a branch which joined the ventral branch of the sixth cervical nerve and helped in the formation of the brachial plexus (Plexus brachialis). The main trunk of the caudal branch continued caudally going medially under the ventral branch of the sixth cervical nerve. Here it received a contributory branch from the ventral branch of the sixth cervical nerve to continue as the phrenic nerve (N. phrenicus). It then traversed caudomedially to enter the

thoracic cavity and lay medial to the axillary vein and artery in close apposition with these structures before it entered the thoracic cavity (Fig. No. 2, 3, 4, 5).

B. Thoracic Cutaneous Nerves (Nn. cutanei thoracici)

The innervation of the skin of the thoracic region was by the cutaneous twigs given off by the thoracic spinal nerves (Nn. spinalis thoracici). The number of thoracic spinal nerves varied depending upon the number of thoracic vertebrae present in a particular specimen and had the same serial number as the vertebra because these emerged through the lateral vertebral foramen instead of intervertebral foramen (Fig. No. 12: Ta'). In the eleven specimens dissected, there were fourteen to sixteen pairs of thoracic spinal nerves. In one case there were sixteen pairs, in seven fifteen pairs and in two cases fourteen pairs of thoracic spinal nerves. In one specimen the nerves of the thoracic region were not counted, as it was dissected for the nerves of the lumbar, sacral and coccygeal regions.

The thoracic spinal nerves had all the characteristics of a typical spinal nerve, except that their ventral branches did not show a division into medial and lateral branches. Otherwise, each spinal nerve was seen to emerge from the lateral vertebral foramen lying along the thoracic vertebra

with the corresponding number and these nerves exhibited a fairly constant manner of origin, course, branching and area of ramification. Like a typical spinal nerve, soon after their emergence from the spinal canal, each thoracic spinal nerve divided into two branches, dorsal and ventral (Fig. No. 11, 12: Ta' and Tb). The dorsal branches further subdivided into medial and lateral branches, while the much larger ventral branches took an oblique caudal course and came to lie in the groove at the caudal border of the rib with the corresponding number to continue ventrally as intercostal nerves (Nn. intercostales) along with the artery and vein of the same name. The ventral branches during their course gave off a number of branches terminating as cutaneous twigs, but these did not subdivide into medial and lateral branches, as indicated previously.

1. Dorsal branches (Rami dorsales)

At the level of the intervertebral foramen, after the division of the thoracic spinal nerve into dorsal and ventral branches, the dorsal branches were completely covered by the Mm. interspinalis and M. multifidus dorsi, traversing a very short distance under these muscles. As soon as the branches reached the cranial part of the mammillary process, each dorsal branch further subdivided into medial and lateral branches. Both these branches finally terminated as the cutaneous twigs-

innervating the dorsal, and dorsolateral aspects of the skin of the thoracic region.

a. The medial branches (Rami mediales) were much smaller than the lateral branches. It has been observed that these branches followed essentially two types of courses depending upon the development of the mammillary processes of the thoracic vertebrae. The mammillary processes of the first ten or eleven thoracic vertebrae were not well-developed, as compared to those of the last five or six thoracic vertebrae, the corresponding medial branches followed a different type of course in both these areas.

1) In four cases, the first eleven, and in six cases the first ten, medial branches of the dorsal branches followed the following course:

Immediately after the subdivision of the dorsal branch into medial and lateral branches, the medial branches stretched obliquely upward in a dorsomedial direction along the M. multifidus dorsi, running almost parallel to the spinous process of the following thoracic vertebra and were completely covered by the M. longissimus dorsi. During their dorsal course these branches gave off a number of small muscular twigs for the innervation of these muscles and, along with the blood vessels, finally pierced through the ligamentum supraspinosus to reach the surface of the skin of the

dorsal aspect of the thoracic region. On the surface of the skin these twigs usually bent laterally and traversed a very short distance to finally ramify in the skin of the dorsal aspect of the thorax. These thin dorsomedial branches were constituted by fewer fibers than the medial branches of the caudal thoracic spinal nerves (Fig. No. 7, 11, 12: Plate No. 7: T₁a' - T₁₀a').

2) In six cases the last five or six, and in four cases the last four or five, medial branches followed the following course:

The dorsomedial branches of the last seven or eight thoracic spinal nerves were given off at the same level as the first seven or eight dorsomedial branches but were stronger and more well-developed than those of the cranial series. Since the mammillary processes were very well-developed in the thoracic vertebrae of the caudal series, the medial branches, soon after their origin, traversed caudally underneath the mammillary process of the following thoracic vertebra and coursed around its ventral surface lying in close apposition to it. After curving around the mammillary process immediately upon emerging below it, these branches took an oblique dorsal course in a dorsomedial direction running almost parallel to the dorsal spinous process of the following thoracic vertebra accompanied by the artery and vein. These were

completely covered in their dorsal course by the M. spinalis thoracis, M. multifidus dorsi and M. longissimus dorsi. Just at the base of the dorsal spinous process of the following thoracic vertebra, the medial branches subdivided into two distinct twigs, though a number of fine muscular twigs were given off at this level for the innervation of these muscles. One of these twigs, traversed caudally to ramify in the muscles of this region, while the other larger twig stretched obliquely in a dorsal direction along with the blood vessels to pierce through the supraspinous ligament reaching the surface of the skin of the dorsal thoracic region. On the surface of the skin the cutaneous twigs bent slightly in a lateral direction and finally ramified in the skin of this region (Fig. No. 7, 12; Plate No. 7: T₁₀a' - T₁₅a').

The aggregate of all the dorsomedial branches of the thoracic spinal nerves appeared to be responsible for the innervation of the skin of the dorsal aspect on either side of the summit of the dorsal spinous processes extending from the first thoracic to the last thoracic vertebra (Fig. No. 6; Plate No. 5: Ta' and Ta").

b. The lateral branches (Rami laterales) were much larger and stronger than the medial branches and took an oblique caudolateral course along the caudal border of the

transverse process of the thoracic vertebra with the corresponding number. The obliquity of their course increased from the first to the last lateral branch, with the maximum in the lateral branches of the last three or four dorsal branches of the thoracic spinal nerves. These showed a fairly constant course and branching except in two cases (Specimens #6 and 10) in which the dorsal branches of the second, third and fourth thoracic spinal nerves gave off two lateral branches. The course followed by the first four lateral branches was different than that followed by the dorsolateral branches of the fifth to tenth and from the eleventh to the last thoracic spinal nerves. Therefore, for the sake of convenience this has been described separately in all three cases. The dorsolateral branches of the second, third and fourth thoracic nerves were the longest of all the dorsolateral branches.

1) In four cases, the dorsolateral branches of the first three and in seven cases of the second, third, fourth, and fifth thoracic spinal nerves followed the same course. As soon as the thoracic spinal nerve emerged from the vertebral foramen it divided into dorsal and ventral branches. Immediately, the dorsal branches further subdivided into medial and lateral branches. The lateral branches traversed laterally lying over the *Mm. levatores costarum* and

dorsally being covered by the M. longissimus dorsi. These then took a caudolateral course to pierce through the M. serratus dorsalis cranialis and came to lie between the M. subscapularis and M. serratus ventralis thoracis on the medial side almost in the middle of the proximal third of the scapula. The dorsolateral branch of the first or second thoracic nerve then perforated the M. subscapularis and the vertebral border of the scapula and appeared on the lateral surface under the M. infraspinatus. After perforating the latter muscle it appeared under the M. trapezius (Pars thoracis). Finally, it pierced the M. trapezius (Pars thoracis) and fascia reaching the skin of the dorsolateral aspect of the scapular region. During its course it gave off a distinct twig for the innervation of these muscles and usually divided into two twigs before ramifying in the skin. The dorsolateral branches of the third and fourth thoracic spinal nerves followed almost exactly the same course as the lateral branches of either the first or second thoracic spinal nerves, except that the dorsolateral branch of the third thoracic spinal nerve lay caudal to the second and that of the fourth lay caudal to the third and perforated through the scapular cartilage close to its caudal angle. (Fig. No. 2: "E_{2a}"-"E_{5a}"). In four cases, where the dorsolateral branch of the fourth thoracic spinal nerve did not perforate through

the scapular cartilage, it curved around the caudal angle of the scapula lying underneath the scapular cartilage to reach the surface of the skin. But irrespective of whether it perforated through the scapular cartilage or curved around the caudal angle of the scapula, its area of ramification was the same in both cases (i.e., the dorsolateral aspect of the skin just caudal to the caudal angle of the scapula). In five cases, it was observed that the dorso-lateral branches of the first thoracic spinal nerve did not reach the surface of the skin. In two cases, it was found that the dorsal branches of the second, third and fourth thoracic spinal nerves gave off two lateral branches. One of these lateral branches took the usual course and either perforated or curved around the caudal angle of the scapula to reach the surface of the skin, while the second lateral branch was distributed in the muscles of this region.

2) The lateral branches of the fifth, sixth, seventh, and eighth thoracic spinal nerves traversed caudolaterally, almost in a sagittal plane, and lay between the *M. longissimus dorsi*, dorsally, and the *Mm. levatores costarum* and *Mm. intercostales interni*, ventrally. After traversing a considerable distance underneath these muscles (nearly 3 cm. from the ventral border of the *M. longissimus dorsi*), it gave off a twig for the innervation of these muscles and then,

traversing caudolaterally, came to lie between the R. longissimus dorsi, dorsally, and the N. iliocostalis thoracis, ventrally. It then traversed a short distance in the fascia, pierced through the M. serratus ventralis thoracis, and came to lie underneath the M. latissimus dorsi (Fig. No. 2, 6: T₂a" - T₅a"; Plate No. 6: T₉a" (K). Before piercing through the latter muscle, those branches divided into two unequal twigs -- one finer and smaller than the other, and both cutaneous twigs perforated through the M. latissimus dorsi to reach the surface of the skin. The smaller finer twig took a dorsomedial course. It was observed that these cutaneous twigs usually alternated with the medial twigs of the dorsal branches which, on the surface of the skin, bent laterally, but these lateral cutaneous twigs never reached the medial twigs of the dorsal branches. These cutaneous twigs were responsible for the innervation of the skin covering the M. longissimus dorsi or the dorsolateral aspect of the thoracic region. The aggregate of all those cutaneous twigs was responsible for the innervation of the skin covering the proximal two-thirds of the ribs. Before ramifications these twigs subdivided into two or three fine twigs (Fig. No. 6: T₂a" - T₁₀a").

The dorsolateral branches of the ninth and tenth thoracic spinal nerves essentially described the same course as the

corresponding preceding branches to appear on the surface of the skin, except that these branches did not perforate through the *M. serratus ventralis thoracis* to reach the surface of the skin (Fig. No. 8, 9: T_{5a}" - T_{10a}").

3) The lateral branches of the eleventh to fifteenth thoracic spinal nerves in seven cases, from the eleventh to sixteenth in one case, and from the eleventh to fourteenth in two cases had the same course, though it was slightly different than that followed by the corresponding branches of the preceding thoracic spinal nerves. The obliquity was maximum in these branches which finally pierced through the *M. serratus dorsalis caudalis*, *M. obliquus externus abdominis* and lumbodorsal fascia to reach the surface of the skin. The last two lateral branches usually extended to the paralumbar region and spread out on the surface of the skin just caudal to the last rib (Fig. No. 6, 8, 9: T_{10a}" - T_{15a}").

The dorsolateral branches of all the thoracic spinal nerves, as stated earlier, before their emergence upon the surface of the skin, subdivided into two unequal twigs which terminated as cutaneous twigs in the areas already described in detail.

2. Ventral branches (Rami ventrales)

The ventral branches were given off immediately after the exit of the thoracic spinal nerves from the foramen vertebralis lateralis ventralis (Fig. No. 11, 12: Tb: 4). These branches first took a caudolateral course, under the Mm. levatores costarum and Mm. intercostales interni. After a short distance, these branches extended in a lateral direction to occupy the groove at the caudal border of the rib with the corresponding number and were called intercostal nerves (Nn. intercostales), except for the ventral branch of the last thoracic spinal nerve. Then, each intercostal nerve traversed ventrally along the curvature of the rib and was accompanied by the intercostal artery and vein in its ventral course under cover of the Mm. intercostales interni and Mm. intercostales externi. However, it has been observed that during its entire course it did not lie between the Mm. intercostales interni and Mm. intercostales externi, except for a very short distance around the middle of the rib where it gave off the perforating branches. Before giving off the perforating branches the intercostal nerves came to lie between these two muscles. It then traversed a short distance along with the perforating branch and returned again to lie underneath the Mm. intercostales interni.

Essentially, all the intercostal nerves had the same course, branching, and pattern of distribution. These followed an oblique caudolateroventral course superficially. The angle of obliquity increased progressively from the first to the last ventral branch of the thoracic spinal nerves and, therefore, the angle of obliquity of the perforating branches also increased accordingly. Except for the first and last ventral branches of the thoracic spinal nerves, each intercostal nerve gave off the following main branches at different levels during its course. These branches usually terminated as cutaneous twigs innervating the skin of the lateral and ventral thoracic wall.

a. The perforating branches (Rami perforante)

1) Lateral cutaneous branches (Rami cutanei laterales)

2) Distal lateral or ventrolateral cutaneous branches (Rami cutanei laterales distales)

b. The ventral cutaneous branches (Rami cutanei ventrales)

1) The ventral branch of the first thoracic spinal nerve (Ramus ventralis N. spinalis thoracicus I), in all the dissected specimens, except two cases, was the smallest of all the ventral branches. The main portion or bulk of this branch traversed cranially to join the ventral branch of the

last cervical spinal nerve contributing in the formation of the brachial plexus (Plexus brachialis). It gave off a small branch which extended caudoventrally along the caudal border of the first rib and was analogous to the intercostal nerve of the following ventral branches. It usually extended just below the middle of the rib and never emerged from the musculature to terminate as a cutaneous twig in eight cases. In two cases, the ventral branch of the first thoracic spinal nerve was very large and well developed and just above the middle of the first rib it perforated through the M. intercostalis interna and M. intercostalis externa to lie under the M. serratus ventralis thoracis (Plate No. 8: R₁). It then took a lateroventral course traversing slightly in a cranial direction and united with the ventral branch of the eighth thoracic spinal nerve. But, it was not found to emerge on the undersurface of the skin to terminate as cutaneous twigs.

2) The ventral branch of the second thoracic spinal nerve (Ramus ventralis N. spinalis thoracicus II) had all the characteristics and branching of a typical intercostal nerve, except that it differed from the rest of the intercostal nerves in a few details. It was the largest and strongest of all the intercostal nerves and, therefore, its cutaneous twigs were most well-developed. Traversing

lateroventrally, near the middle of the second rib it pierced through the M. intercostalis interna to give off a perforating branch (Ramus perforantis) which traversed for a short distance between the M. intercostalis interna and M. intercostalis externa. It then perforated the M. intercostalis externa to take an oblique caudoventral course lying underneath the M. serratus ventralis thoracis towards the elbow joint. At the caudal border of the M. serratus ventralis thoracis it divided into two strong, well-developed, unequal twigs -- one smaller than the other. The smaller, lateral cutaneous twig (Ramus cutaneus lateralis) traversed laterally while the larger, distal lateral cutaneous twig (Ramus cutaneus distalis lateralis), took a more prominent ventrolateral course. Both of these twigs innervated the skin caudal to the thoracic limb while the lateral cutaneous twig, in addition, supplied a patch of skin in the region of the elbow joint (Fig. No. 7, 8, 9, 10: Tb''' and Tb''').

La c. The perforating branches of the intercostal nerves (Rami perforantes intercostales). Each ventral branch of the thoracic spinal nerve just below or at the middle of the corresponding rib, gave off a perforating branch which pierced through the M. intercostalis interna and traversed a short distance lying between the M. intercostalis interna

and M. intercostalis externa. At the level of the distal one-third of the ribs these branches pierced through the M. intercostalis externa and the superficial muscles to reach the surface of the skin (Fig. No. 2, 8, 9, 10, 11, 12; Plate No. 8, 9, 10: T₃b" - T₁₄b"). Just before perforating through the superficial muscles, each perforating branch subdivided into two unequal branches or twigs, the smaller lateral cutaneous branch or twig (Ramus cutaneus lateralis) traversed laterally and the larger distal lateral or ventrolateral cutaneous branch or twig (Ramus cutaneus distalis lateralis) traversed to innervate the ventrolateral aspect of the skin of the thoracic region. The course followed by the first seven or eight lateral cutaneous branches or twigs was somewhat different than that followed by the last seven or eight lateral cutaneous branches or twigs to reach the surface of the skin, though the area of distribution and ramification was essentially the same in both groups.

1) Lateral cutaneous branches (Rami cutanei laterales)

a) The first seven or eight perforating branches reached the surface of the skin after piercing through the M. serratus ventralis thoracis at the caudal border of the M. latissimus dorsi. Here they divided into two cutaneous branches or twigs before emerging from the M.

latissimus dorsi. The smaller lateral cutaneous branch or twig traversed slightly obliquely in a ventral direction. The lateral cutaneous branch or twig of the third and fourth perforating branches emerged from the musculature at the level of the olecranon process of the ulna and then traversed caudoventrally to innervate the skin of the cranioventrolateral aspect of the thoracic wall, caudal to the elbow joint. The rest of the lateral cutaneous branches or twigs, as well, followed the same course to reach the surface of the skin. On the skin, these branches further subdivided into two or more fine twigs which extended in a dorsal direction and were responsible for the innervation of the skin of the middle part of the thoracic wall (Fig. No. 2, 8, 9, 10: $T_2^{b''}$ - $T_{10}^{b''}$; Plate No. 8, 9, 10: Tb'').

b) The last six or seven lateral cutaneous branches or twigs essentially had the same course as that of the first seven or eight lateral cutaneous branches, except that the obliquity of their course was well marked and the branches finally pierced through the *M. obliquus externus abdominis* to reach the skin. On the surface of the skin these also subdivided into two or more fine cutaneous twigs and spread out on the skin of the middle part of the thoracic region and cranial part of the abdominal wall. (Fig. No. 8, 9, 10: $T_{10}^{b''}$ - $T_{15}^{b''}$; Plate No. 8, 9, 10: Tb'').

2) Distal lateral cutaneous branch or ventrolateral cutaneous branch (Rami cutanei laterales distales)

In nine cases out of eleven specimens dissected the perforating branches subdivided into lateral cutaneous branches (Rami cutanei laterales) and distal lateral cutaneous branches (Rami cutanei laterales distales), while in two cases, the last two perforating branches did not subdivide into two cutaneous branches. The lateral cutaneous branches were very well developed and gave off a number of fine cutaneous twigs during its course which were analogous to those followed by the distal lateral cutaneous branches. These branches traversed a considerable distance superficially and divided into two cutaneous twigs before spreading out on the surface of the skin of the ventrolateral aspect of the thoracic region. The second branch of the perforating branches is called the distal lateral cutaneous branch. It was much larger and stronger than the lateral cutaneous branches and traversed in an oblique caudventral course on the surface of the skin lying over the superficial muscles of the region and the fascia. The distal lateral cutaneous branch of the third, fourth and fifth perforating branches (Rami perforante intercostales) lay superficially between the *M. pectoralis caudalis profundus* and the skin, while the rest of the distal lateral cutaneous branches lay between

the M. obliquus externus abdominis and the skin (Fig. No. 9, 10, 11, 12: Tb').

d. Ventral cutaneous branches (Rami cutanei ventrales)

The intercostal nerves, after giving off the perforating branches, coursed a very short distance between the Mm. intercostales interni and Mm. intercostales externi in a ventrolateral direction and then returned to lie under the Mm. intercostales interni. Along with the intercostal vessels (A. and V. intercostales), these first extended ventrally and then cranioventrally to reach the costochondral junction. Finally, these intercostal nerves perforated the musculature at the costo-sternal junction to reach the surface of the skin of the ventral aspect, where they spread out as cutaneous branches and are called the ventral cutaneous branches (Fig. No. 11, 12:Tb'). All the intercostal nerves finally terminated as ventral cutaneous branches. In most cases, the second to fourteenth intercostal nerves, inclusive, terminated as ventral cutaneous branches, while in two cases, the last two or three intercostal nerves spread out on the M. rectus abdominis. Moreover, the intercostal nerves of the sternal ribs (first 8 pairs) followed a different course than those of the asternal ribs. Therefore, the course followed by the ventral cutaneous branches of these two types of intercostal nerves was also different.

1) The ventral cutaneous branches of the sternal ribs followed a very marked cranial course to lie along the lateral surface of the corresponding sternabrae and then came to lie between the M. pectoralis cleidoscapularis, through which these pierced to reach the surface of the skin of the mid-ventral region lying caudal to the brisket region. On the surface of the skin these branches divided into small fine twigs to ramify in the skin of this region (Fig. No. 2, 9, 10, 11: Tb').

2) The ventral cutaneous branches of the asternal ribs followed a slightly oblique ventral course extending in the M. obliquus internus abdominis and then passed between the M. transversus abdominis and M. rectus abdominis. All the intercostal nerves of the asternal ribs did terminate as ventral cutaneous branches. Usually the last three intercostal nerves gave off some muscular twigs which spread out on the M. rectus abdominis. All the intercostal nerves of the asternal ribs finally pierced through the M. rectus abdominis and fascia to reach the skin and terminated as ventral cutaneous twigs (Rami cutaneus ventrales) (Fig. No. 2, 9, 10: T₈b' - T₁₅b'). These branches were responsible for the innervation of the ventral aspect of the thoracic and abdominal regions. The aggregate of all the ventral

cutaneous branches innervated the skin on both sides of the mid-ventral line (Fig. No. 2, 9, 10: Tb').

3) The ventral branch of the last thoracic spinal nerve is not called as intercostal nerve and it had some marked differences from the ventral branches of the thoracic spinal nerves preceding it. It left the spinal canal on each side at the caudal end of the last thoracic vertebra, and was so placed that it appeared to be at a considerable distance from the last rib. After its emergence, it took an oblique caudolateral course running almost parallel to the last rib to reach the lateral border of the *M. quadratus lumborum*. At this level, along with the cranial-most branch of the *A. phrenica-abdominalis*, it entered the *M. transversus abdominis* at its vertebral border. After traversing a considerable distance at the upper third of the abdominal wall, it divided into two unequal branches, one smaller than the other. After a short distance it pierced the *M. obliquus externus abdominis* and *M. cutanei trunci* to spread out on the skin of the middle of the abdominal wall (cranial part). During its course it gave off some muscular twigs to these muscles. The second or larger branch continued in a caudo-ventral direction lying on the *M. transversus abdominis* to enter the *M. rectus abdominis* at its lateral border on which it finally spread out. In some cases, it was seen giving

off a cutaneous twig near the umbilicus and it took part in the innervation of the skin of the mammary glands (Fig. No. 10: Tb').

C. Lumbar Cutaneous Nerves (Nn. cutanei lumbales)

The innervation of the skin of the lumbar region was mainly by the branches of the lumbar spinal nerves (Nn. spinales lumbales). In all, except one, of the eleven specimens dissected, there were six pairs of lumbar spinal nerves (Nn. spinales lumbales) and one had five pairs. All the nerves emerged through the intervertebral foramen situated between the two adjacent lumbar vertebrae, except the last lumbar spinal nerve (N. spinalis lumbalis VI), which emerged between the last lumbar and the first sacral vertebrae (Fig. No. 12, 15). Each lumbar spinal nerve had the characteristics of a typical spinal nerve and, as a whole, as soon as the nerves left the intervertebral foramen they divided into two rami, a dorsal and a ventral one. This was so in the case of the first and second lumbar nerves (Nn. spinales lumbales I and II). As in the case of the succeeding nerves, the division took place inside the vertebral canal and then gained exit. They separated immediately after their emergence and were separated by the intertransverse ligaments, over which the dorsal branches of the nerve lay and traversed

outwardly, stretching over the transverse process of the following vertebra, while the ventral branches took an oblique course lying under the transverse process of the following vertebra. The dorsal branches were much larger than the dorsal branches of the thoracic region, stronger and well developed and followed a more oblique outward course ventrolaterally than the corresponding branches of the thoracic region. Moreover, these nerves were seen to be embedded in the *M. longissimus dorsi*, while the corresponding nerves of the thoracic region lay underneath this muscle.

1. Dorsal branches (Rami dorsales)

These were typically similar to each other, with a similar disposition, branching and ramification. Each dorsal branch of the *Nn. spinales lumbales* traversed a short distance under cover of the *M. multifidus dorsi* and then, at the level of the mammillary process, divided into two unequal branches -- a larger and stronger lateral branch and a smaller and finer medial branch. Both took a different course to reach the surface of the skin, one for the dorsal aspect and the other for the dorsolateral aspect of the paralumbar region (Fig. No. 7; Plate No. 11: L_1a' - L_6a' and L_1a'' - L_6a'').

a. As stated above, the smaller and finer medial branches (Rami mediales) were given off at the level of the mammillary processes (at the cranial edge) under cover of the *M. longissimus dorsi* (Fig. No. 7; ; Plate No. 11: $L_1a' - L_5a'$). Immediately these branches took a caudal course underneath the mammillary process of the following vertebra lying in close apposition with the ventral surface of the mammillary process, except the last which went over the first sacral segment. As soon as it left the mammillary process it ascended dorsally, meeting the dorsal branches of the *Aa. lumbalia* lying underneath the *M. multifidus dorsi* and the *M. longissimus dorsi*. After traversing a short distance dorsal along with the dorsal branches of the *Aa. lumbalia* lying in close relation to the dorsal spinous process of the following vertebra, it gave off a number of fine twigs for the innervation of the *M. multifidus dorsi*. However, one fine twig ascended dorsally with the blood vessels along with the spinous process and finally pierced through the supraspinous ligament and the lumbar fascia to appear on the dorsal aspect of the lumbar region (Fig. No. 7, 8, 9, 13; Plate No. 5, 11: $L_1a' - L_5a'$). After piercing through the lumbar fascia it bent laterally on the same side of the body, ran under the subcutaneous tissue caudoventrally almost to the level of the imaginary horizontal line drawn at the level

of the tuber coxae. It was observed that although these cutaneous twigs did not ascend to the same level dorsally they alternated with the cutaneous twigs of the lateral branches which took a caudodorsal course on the surface of the skin after their emergence from the N. longissimus dorsi (Fig. No. 8, 9, 13). This pattern of course and distribution of the dorsal branches of the Nn. spinales lumbales is another explanation of the findings by Arnold and Kitchell (1957), in their investigations regarding dermatomes of the abdominal wall of cattle.

b. As stated above, the stronger and larger lateral branches (Rami laterales) lay over the M. intertransversales lumborum and were completely covered dorsally by the R. longissimus dorsi. These branches took an oblique latero-caudal course, lying over the transverse process of the following lumbar vertebra (Fig. No. 7, 8, 9, 10: Plate No. 11: L₁a" - L₅a"). The first two lateral branches traversed a considerable distance underneath the M. longissimus dorsi and then, just before reaching the ventral border of this muscle, these branches pierced into the muscle and then, after traversing a short distance in it, finally, at the level of the ventral border, perforated through the muscle as the cutaneous twigs (Fig. No. 8, 9, 10: Plate No. 5, 6, 11: L₁a" - L₅a"). The last four lateral branches initially

followed the same course in relation to the muscles as that of the first two but, after traversing a short distance almost in the middle, these branches went into the *M. longissimus dorsi* and traversed a considerable distance latero-caudally while embedded in this muscle, finally piercing through the muscle at the level of its ventral border to emerge as the cutaneous twigs. During their course, these branches gave off a number of distinctive twigs for the innervation of the *M. longissimus dorsi*. After their emergence from the musculature, these branches divided into two distinct cutaneous twigs, one of which was much finer than the other. The finer twig pierced through the lumbodorsal fascia to reach the undersurface of the skin, where it pursued a caudodorsal course alternating with the cutaneous twigs of the medial branches and was responsible for the innervation of the skin of the dorsolateral aspect of the lumbar region. The other much stronger twig took an oblique caudal course along the dorsal border of the *M. iliocostalis lumborum*. It traversed some distance and lay superficially embedded in the deep fascia which it finally perforated to reach the undersurface of the skin. The first three of these cutaneous twigs were seen to reach a plane horizontal with the stifle joint and transverse planes passing through the caudal border of the first lumbar and cranial border of the

sixth lumbar vertebra, and ramified in the skin of this region. The last three cutaneous twigs took a much more oblique caudal course and covered a wide area extending in a curved line through the hip joint to the stifle joint, with its convexity directed caudally, and finally ramified in the skin of this region (Fig. No. 7, 9, 10,13; Plate No. 6: L₁a" - L₆a"). It was seen that the last two twigs came to lie superficially over the M. gluteus superficialis and ramified in the skin of the rump region (Fig. No. 10, 13; Plate No. 6: L₁a" - L₆a").

2. Ventral branches of the lumbar spinal nerves (Rami ventrales Nn. spinales lumbales)

The ventral branches of the lumbar spinal nerves were much stronger and larger than the dorsal branches and lay under the M. intertransversalis lumborum in their oblique caudoventral course. Each nerve further divided into a variable number of branches, some of which terminated as cutaneous twigs. Since, in these studies, the nerves arising from the lumbosacral plexus were not fully investigated in detail, the observations reported will mainly cover the first to fourth lumbar spinal nerves while only general information regarding the fifth and sixth lumbar spinal nerves is included.

a. The first lumbar spinal nerve (N. iliohypogastricus) gave off a small fine twig to the second lumbar spinal nerve as soon as it emerged. It passed over the M. quadratus lumborum and at its lateral border divided into two main branches traversing obliquely caudoventrally and came to lie under the transverse process of the second lumbar vertebra (Fig. No. 14; Plate No. 12: L₁b). It then passed into the subserous transversalis fascia of the abdomen and during this course its two branches accompanied the two caudal branches of the A. phrenico-abdominalis. The two branches can be named cranial and caudal due to their position. The smaller cranial branch (lateral branch) passed through the M. obliquus internus abdominis and took a lateral caudoventral course lying between the preceding muscle and the M. obliquus externus abdominis (Fig. No. 8, 9, 10, 12, 13; Plate No. 9, 10, 12: L₁b'). In its course through these muscles it gave off some twigs for the innervation of these muscles. Near the middle of the abdomen, it perforated the M. obliquus externus abdominis to become subcutaneous and usually divided into two twigs. The smaller finer twig was distributed in the skin covering this region while the larger twig was distributed in the skin of the ventrolateral aspect covering the middle third of the abdominal wall caudal to the last rib.

The caudal branch (medial branch) was larger than the cranial branch and went inwardly to lie between the M. obliquus internus abdominis and the M. transversus abdominis taking a lateral, caudoventral course. During its course it gave off twigs to both of these muscles and finally passed between the M. transversus abdominis and the peritoneum to reach the lateral border of the M. rectus abdominis. At this level it gave off a cutaneous twig which perforated through the M. rectus abdominis and innervated the skin of the region (Fig. No. 9, 10, 13 ; Plate No. 12: L₁b").

In the specimen which had five pairs of lumbar spinal nerves it seemed that the N. iliohypogastricus was missing anatomically, but the last pair of thoracic spinal nerves were distributed in exactly the same area which was normally supplied by the N. iliohypogastricus.

b. Soon after emerging through the intervertebral foramen, the second lumbar nerve (N. ilioinguinalis) also divided into cranial and caudal branches as did the first lumbar nerve (Fig. No. 14, 13 ; Plate No. 12: L₂b). It had essentially a similar course as the first lumbar nerve, lying caudal to it. The small twig given off by the first lumbar spinal nerve, as described earlier, united with the cranial branch of the second lumbar spinal nerve. This branch followed an oblique caudoventral course and further divided into

two twigs. One of these twigs pierced the abdominal fascia at the level of the upper one-third of the lateral abdominal wall, and ramified in the skin of this area. The second muscular twig ramified in the N. obliquus externus abdominis (Fig. No. 9, 10, 13, 14; Plate No. 9, 10, 12: L₂b').

The caudal branch further divided into two branches, cranial and caudal, named according to their position. The cranial subdivision traversed caudally along the dorsal aspect of the M. psoas major and lay under the transverse process of the third lumbar vertebra. After traversing a short distance at this level it again divided into two unequal twigs. The smaller twig was cranial to the larger twig and was accompanied by the middle branch of the A. phrenico-abdominalis. It passed between the N. obliquus internus abdominis and the M. obliquus externus abdominis running in a caudoventral direction. After reaching the middle of the abdominal wall it perforated the M. obliquus externus abdominis to emerge on the surface of the skin lying caudal to the corresponding branch of the first lumbar spinal nerve (Fig. No. 9, 10, 13: Plate No. 9, 10, 12: L₂b'). On the surface of the skin it had a similar course and traversed ventrally, lying superficially under the skin and finally ramifying in the skin covering the ventrolateral aspect of the abdominal wall just caudal to that of the first lumbar spinal nerve. The larger twig of the cranial

branch went between the M. obliquus internus abdominis and M. transversus abdominis and, after giving some twigs to these muscles, finally was distributed in the M. rectus abdominis (Fig. No. 13, 14 ; Plate No. 12: L₂b").

The secondary branch of the caudal division ran more or less parallel to the preceding branch and was almost embedded in the M. psoas major which it perforated at its lateral border to emerge there. After traversing a short distance it passed between the M. obliquus internus abdominis and the M. transversus abdominis and divided into two twigs. One of the twigs innervated these muscles. The other continued in a caudoventral direction in the M. obliquus internus abdominis and gave some fine twigs for the innervation of this muscle, finally appearing as a cutaneous twig in the inguinal region and was responsible for the innervation of the skin of the mammary glands and prepuce.

c. The ventral branch of the third lumbar spinal nerve emerged from the vertebral canal lying between the third and fourth lumbar vertebrae over the sublumbar muscles. It was a strong and well-developed branch and, immediately after the emergence divided into three branches. Two of these were short twigs while the third one was much larger and seemed to be the continuation of the main trunk (Fig. No. 14; Plate No. 12: L₃b).

These two twigs usually received a short twig from the ventral branch of the second lumbar spinal nerve and innervated the M. psoas major and M. psoas minor. In any of the specimens dissected the third lumbar spinal nerve was not seen giving off any twigs which united with the cutaneous branch of the second lumbar spinal nerve to reach the undersurface of the skin.

The third branch, or the main trunk, continued to traverse in a medial direction lying between the M. psoas major and M. psoas minor and taking a caudoventral course almost parallel with the vertebral column. It extended to the level of the fifth lumbar vertebra following the above stated course and, at this level before it emerged through the musculature, it gave off a small twig which united with the ventral branch of the fourth lumbar spinal nerve (Fig. No. 14: L₃b ; Plate No. 12). It then emerged through these muscles and continued in a ventrocaudal direction. At the level of the cranial border of the transverse process of the sixth lumbar vertebra it gave off a well developed twig which united with a branch of the fourth lumbar spinal nerve and contributed to the formation of the lateral cutaneous nerve of the thigh (N. cutaneus femoris lateralis). (Fig. No. 14; Plate No. 12: F).

In most of the cases, it was seen that the third lumbar spinal nerve also received a small communicating branch from the fourth lumbar spinal nerve in return. In some cases it was observed that there were a number of small communicating twigs instead of two or three small twigs. The main trunk of the third lumbar spinal nerve continued as the N. spermaticus externus (or appropriately called the N. genitalis) and did not seem to give off cutaneous twigs to the area under consideration.

d. The ventral branch of the fourth lumbar spinal nerve emerged from the intervertebral foramen between the fourth and fifth lumbar vertebrae lying in close apposition with the lateral side of the ventral spinous process. It then took a caudoventral course along with the body of the fifth lumbar vertebra (Fig. No. 14: L₄b ; Plate No. 12: L₄b). It pierced between the M. psoas major and M. psoas minor. It traversed a short distance in this course to emerge from these muscles at the level of the caudal end of the fifth lumbar vertebra. Before its emergence from the musculature, it divided into two branches. The smaller one lay cranially while the larger, or main branch of the fourth lumbar spinal nerve, took a caudoventral course. The smaller cranial branch traversed cranioventrally lying over the M.

psoas major et minor and received a small twig from the third lumbar spinal nerve. It then left the musculature traversing ventrally and soon after it received another twig from the main branch (N. genitalis) of the third lumbar spinal nerve. At this point this branch of the fourth lumbar spinal nerve also gave off a twig which united with the third lumbar spinal nerve.

The main branch of the fourth lumbar spinal nerve, as stated earlier, took a lateral, caudoventral course to cross obliquely the caudal third of the M. psoas major and M. psoas minor and the origin of the M. iliacus at the level of the tuber coxae. In most of the cases, at this level it coursed between the M. obliquus internus abdominis and the os ilium, while in some cases it pierced the coxal origin of the M. obliquus internus abdominis to reach finally the deep surface of the M. tensor fascia latae (Plate No. 12: F). Before this, it divided into two equal branches which traversed ventrally, lying on the deep face of the M. tensor fascia latae along with the descending branch of the A. circumflexa ilium profunda and its satellite veins and each branch again divided into two, resulting in four twigs. Two of the twigs took a slightly cranial course and ran in front of the thigh and the stifle joint. Finally these twigs were distributed

over the skin of the lateral aspect of the thigh and in the fold of the flank region. One of these continued to traverse as a cutaneous twig on the lateral aspect of the leg. The other two twigs coursed towards the inguinal region (Fig. No. 8, 9, 10, 12; Plate No. 9, 10, 12: F).

e. The N. cutaneus femoris lateralis, in all the dissected specimens, was formed by the branches of the third and fourth lumbar spinal nerves. In all these cases, it was observed that the main branch of the fourth lumbar spinal nerve (as described above) continued laterally, caudally and ventrally to be known as the N. cutaneus femoris lateralis, while it always received one or more contributory twigs from the main branch of the third lumbar spinal nerve. The second lumbar spinal nerve did not contribute any twig to this nerve. In one case, which had five pairs of lumbar spinal nerves, the N. cutaneus femoris lateralis was formed by the main branch of the third lumbar spinal nerve while the second lumbar spinal nerve was seen to contribute small twigs. As previously described, this nerve, below the level of the coxal origin of the M. obliquus internus abdominis, divided into two branches which traversed caudoventrally lying on the deep face of the M. tensor fascia latae. At the level of the subiliac lymph nodes, these further subdivided, resulting in the formation of four twigs. The course and area

of ramification of these twigs have already been described. (Fig. No. 8, 9, 10, 12, 13, 14; Plate No. 12: F).

f. The fifth lumbar spinal nerve emerged through the intervertebral foramen between the fifth and the sixth lumbar vertebrae. It also took an oblique, lateral, caudo-ventral course and was much larger and stronger than the preceding lumbar spinal nerves. It received contributory twigs from the fourth lumbar spinal nerve and finally united with the sixth lumbar spinal nerve to form the lumbosacral plexus (Fig. No. 14: L₅b; Plate No. 12: L₅b). The branching of this nerve was not investigated, as it was not seen to give off any twigs terminating on the skin of the regions under consideration in the present studies.

g. The well-developed sixth lumbar spinal nerve emerged from the intervertebral foramen between the last lumbar and first sacral vertebrae. It lay close to the body of the vertebra and traversed caudally to cross the sacral promontory, lying in its deep notch. It was joined by the ventral branches of the fifth lumbar and first and second sacral spinal nerves, resulting in the formation of the flattened trunk of the lumbosacral plexus (Fig. No. 14: L₆b, S₁b; Plate No. 12: L₆b). The further branchings of this nerve have not been investigated, as no cutaneous twigs were given off by this nerve for the innervation of the skin of the region investigated in these studies.

D. Sacral Cutaneous Nerves (Nn. cutanei sacrales)

In the eleven specimens dissected there were four pairs of sacral spinal nerves. The sacral spinal nerves had all the characteristics of a typical spinal nerve and, in general, had a similar disposition as that of the lumbar spinal nerves with certain peculiarities. It appeared that the division of the sacral spinal nerves into dorsal and ventral roots occurred within the sacral canal and both the dorsal and ventral branches emerged from the dorsal and ventral sacral foramina lying posterior to the sacral segment with the corresponding number. The last sacral spinal nerve emerged from the spinal canal by passing through the intervertebral foramina, between the sacrum and first coccygeal vertebrae like the other typical spinal nerves. Moreover, the dorsal branches were much longer than the ventral branches, while the ventral branches were stronger than the dorsal branches.

1. Dorsal branches of the sacral spinal nerves (Rami dorsales Nn. spinales sacrales)

The dorsal branches of the first three sacral spinal nerves left the three dorsal sacral foramina while the fourth sacral spinal nerve emerged from the intervertebral foramen between the last sacral and the first coccygeal

vertebrae. Immediately after its emergence, it divided into two unequal branches, which can be called the medial and lateral branches, according to the course taken up by them. The lateral branches were much larger than the medial branches and these ultimately terminated as the cutaneous twigs for the innervation of the skin of this region (Fig. No. 13: S₁a" - S₃a").

a. The medial branches as stated above were much smaller than the lateral branches and were given off as soon as the dorsal branches emerged from the dorsal sacral foramina. The medial branch of the first dorsal branch took a caudal course lying under cover of the *M. sacrococcygeus dorsalis* and united with the medial branch of the second dorsal branch of the sacral spinal nerve. The medial branch followed a similar course to join the medial branch of the third dorsal branch of the sacral spinal nerve which, in turn, traversed caudally and joined the corresponding branch of the fourth sacral spinal nerve leading to the formation of the dorsal sacral trunk. As has been observed in the case of the dorsomedial branches of the thoracic and lumbar spinal nerves (*Mn. spinales thoracici et lumbales*), the dorsomedial branches of the sacral spinal nerves did not emerge on the surface of the skin to terminate as the dorsal cutaneous twigs. The dorsal sacral trunk during its course gave off

a number of twigs which were responsible for the innervation of the *M. sacrococcygeus dorsalis medialis* and *M. sacrococcygeus dorsalis lateralis*. However, none of these twigs could grossly be dissected to reach the skin of the dorsal sacral aspect. The dorsomedial branches of the sacral spinal nerves grossly seemed to be the muscular branches only, as none of them had any dissectable cutaneous twigs. The medial branches from the first to last sacral nerves appeared to be of the same size, though it was observed that the number of twigs seemed to decrease from the first to the last medial branch of the dorsal branch of the sacral spinal nerves. The dorsomedial branch of the last sacral spinal nerve (*N. spinalis sacralis IV*) had three or four twigs only and was thinner, comparatively, than the first dorsomedial branch. It continued caudally to join the dorsal branch of the first coccygeal spinal nerve (*N. spinalis coccygeus I*) and helped in the formation of the dorsal coccygeal trunk (Fig. No. 15; Plate No. 13: Cy').

b. The lateral branches were much longer than the medial branches with their size decreasing from the first to the last dorsolateral branch of the sacral spinal nerve, with the first one being the longest. At their origin, these were completely covered by the *M. sacrococcygeus dorsalis lateralis* and *M. sacrococcygeus dorsalis medialis* and then these branches

took a lateral course traversing caudodorsally, lying between the *M. sacrococcygeus dorsalis lateralis* and *M. sacrococcygeus dorsalis medialis*. It then came to lie between the *M. sacrococcygeus dorsalis lateralis* and *Mm. intertransversarius dorsalis caudae* to reach the deep gluteal fascia. The first three dorsolateral branches perforated the deep gluteal fascia to reach the surface of the skin, finally terminating as the cutaneous twigs which were chiefly responsible for the innervation of the skin of the gluteal region.

1) The dorsolateral branch of the first sacral spinal nerve (*N. spinalis sacralis I*) was usually seen to be joined by the twigs of the dorsolateral branch of the sixth lumbar spinal nerve (*N. spinalis lumbalis VI*) and then it traversed laterally in a caudodorsal direction lying underneath the *M. sacrococcygeus dorsalis lateralis*. After traversing a short distance it pierced this muscle and lay superficially under the gluteal fascia, usually one and a half to two inches caudal to the tuber coxae. It then traversed obliquely in a ventrocaudal direction lying above the *M. gluteobiceps* and, in the middle of the gluteal region, it perforated the gluteal fascia. Before its emergence it divided into two thin cutaneous twigs which continued to run caudoventrally on the *M. gluteobiceps* and down the thigh. These two cutaneous twigs finally were distributed in the

skin of the gluteal region and the lateral aspect of the thigh (Fig. No. 13: S₁a").

2) The dorsolateral branch of the second sacral spinal nerve (N. spinalis sacralis II) had almost the same course as that of the corresponding branch of the first sacral spinal nerve (N. spinalis sacralis I) except that it was smaller than the first one and lay caudal to it. It also took a caudoventral course lying superficially on the M. gluteobiceps and finally was distributed in the skin of the caudal and lateral aspects of the gluteal and thigh regions. It separated into small, finer twigs during its course and final distribution (Fig. No. 13: S₁a" - S₃a").

3) The dorsolateral branch of the third sacral spinal nerve (N. spinalis sacralis III) was the smallest of all these branches and had the same course as that of the preceding two corresponding branches of the first and second sacral spinal nerves (Nn. spinales sacrales I et II), except that it followed a more ventrocaudal course on the M. gluteobiceps than those of the preceding branches lying caudal to them. It stretched towards the skin of the region though it was not seen, in any case, to reach that far. It finally ramified in the skin of the caudal aspect of the gluteal region (Fig. No. 13: S₃a").

4) The dorsal branch of the fourth sacral spinal nerve (N. spinales sacralis IV) was not found to give off a distinct dorsolateral branch terminating as a cutaneous twig. The aggregate of these three dorsolateral cutaneous twigs was responsible for the innervation of the skin covering the lateral and caudal aspects of the gluteal and thigh regions (Fig. No. 15). These three cutaneous twigs are analogous to the middle clunial nerves (Nn. clunii medi) of Ellenberger and Baum (1943).

2. Ventral branches of the sacral spinal nerves (Rami ventrales spinales sacrales)

A detailed investigation was not carried out to study the manner of branching, communication and areas of ramifications of the ventral branches of the sacral spinal nerves as these nerves were closely associated in the formation of the lumbosacral plexus (Plexus lumbosacralis) from which a number of branches arose for the innervation of the structures of the pelvic cavity. Moreover, only one major branch was given off the ventral branches of the sacral spinal nerves which finally terminated as a cutaneous twig in the adjoining area of the skin presently investigated. However, to observe the general pattern of these nerves, studies were carried out in three of the eleven dissected specimens. The ventral

branches of the sacral spinal nerves left the spinal canal through the ventral sacral foramina, except the last, which emerged from the intervertebral foramen between the last sacral segment and the first coccygeal vertebra. These branches were stronger and more well-developed than those of the dorsal branches and intercommunicated with each other.

a. The ventral branch of the first sacral spinal nerve (Ramus ventralis sacralis I) emerged from the spinal canal through the first ventral sacral foramen and was a strong, well-developed cord. It traversed caudolaterally along the ventral surface of the respective vertebra to reach the medio-caudal border of the wing of the sacrum. At this level it was joined by the ventral branch of the last lumbar spinal nerve (N. spinalis lumbalis VI) which carried fibers from the preceding two lumbar spinal nerves, and the ventral branch of the second sacral spinal nerve (N. spinalis sacralis II), resulting in the formation of the lumbosacral plexus. From this plexus a number of branches were given off for the innervation of the various structures of the pelvic cavity (Fig. No. 14: S₁b; Plate No. 12: S₁b).

b. The ventral branch of the second sacral spinal nerve (Ramus ventralis N. spinalis sacralis II) was much smaller than the ventral branch of the first sacral spinal nerve. It left the spinal canal through the second ventral sacral

foramen and immediately divided into two unequal branches. The larger branch, which was formed by the bulk of the ventral branch of the second sacral spinal nerve, traversed somewhat cranially and joined with the ventral branch of the first sacral spinal nerve (N. spinales sacralis I) to help in the formation of the lumbosacral plexus (Fig. No. 14: S₂b).

The smaller branch further gave off two or more twigs, one of which joined with the third sacral spinal nerve (N. spinalis sacralis III) and contributed in the formation of the N. cutaneus femoris caudalis (Fig. No. 14: S₂b and S₃b).

c. The ventral branch of the third sacral spinal nerve (Ramus ventralis N. spinalis sacralis III) left the sacral canal through the third ventral sacral foramen, between the third and fourth sacral segments. It was much smaller than the preceding two nerves and seemed to be constituted by a much smaller number of twigs. Immediately after its emergence it received a twig from the ventral branch of the second sacral spinal nerve and it, as well, gave off a small twig which joined the ventral branch of the fourth sacral spinal nerve. In the specimens dissected it was observed that the main combination of the third sacral spinal nerve continued caudolaterally as the N. cutaneus femoris caudalis

which, after a short course through the sacrosciatic attachment of the M. biceps femoris and M. semitendinosus, pierced through the above named muscles and was distributed in the skin of the anal and perineal regions. During its course it gave off a number of muscular twigs which were responsible for the innervation of the muscles of the perineum (Fig. No. 13: D).

d. The ventral branch of the fourth sacral spinal nerve (Ramus ventralis N. spinalis sacralis IV) was the smallest of all the sacral spinal nerves and emerged from the sacral canal through the intervertebral foramen between the last sacral segment and the first coccygeal vertebra. In most of the cases, it traversed caudally, united with the ventral branch of the first coccygeal spinal nerve (N. spinalis coccygeus I) and contributed in the formation of the ventral coccygeal trunk. In two cases it gave off fine twigs which traversed caudolaterally on the M. biceps femoris and M. semimembranosus and terminated as the cutaneous twigs innervating the skin of the area caudal to the anus (Fig. No. 14, 15a: S₄^b).

E. Coccygeal Cutaneous Nerves (Mn. cutanei coccygei)

The innervation, dorsal and ventral aspects, of the skin of the tail was accomplished by the branches given off by the coccygeal spinal nerves. The number of coccygeal spinal nerves was variable, from four to eight pairs. Out of eleven specimens dissected, in eight cases there were six pairs, in two cases four pairs, and in one case there were eight pairs of coccygeal spinal nerves. The coccygeal spinal nerves emerged from the vertebral canal through the intervertebral foramen and were seen lying caudal to the coccygeal vertebra with the corresponding number. The first coccygeal spinal nerve emerged from the intervertebral foramen between the first and second coccygeal vertebrae and followed the same pattern as did the rest of the coccygeal spinal nerves. These, immediately after their emergence, divided into two branches, dorsal and ventral. The dorsal branches traversed dorsally over the transverse process of the following coccygeal vertebra and the Mm. intertransversarii dorsalis caudae (Fig. No. 15a: **CyI** ; Plate No. 13: $Cy_1a - Cy_6a$). The ventral branches coursed ventrally to the transverse process of the following vertebra and the Mm. intertransversarii ventralis caudae covered by the M. sacrococcygeus ventralis medialis (Fig. No. 15a; Plate No. 14: $Cy_1b - Cy_6b$).

1. Dorsal branches (Rami dorsales)

The dorsal branches were smaller than the ventral branches. The dorsal branch of the first coccygeal spinal nerve (N. spinalis coccygeus I) was joined by the twigs given off by the dorsal branch of the fourth sacral spinal nerve (N. spinalis sacralis IV). (Fig. No. 15a: S IV ; Plate No. 13: Cy₁a). The dorsal branches subdivided into medial and lateral branches. The subdivision in the first three to four pairs was clearly marked and distinctive while it appeared to be lost in the rest of the dorsal branches of the coccygeal spinal nerves. When the dorsal branches of the coccygeal spinal nerves was clearly divided into medial and lateral branches, the division was seen immediately at its emergence from the intervertebral foramen. The medial branches were thinner than the lateral branches and were seen traversing under the transverse process of the following coccygeal vertebra and then stretched dorsally, lying under cover of the Mm. intertransversarii dorsalis caudae towards the M. sacrococcygeus dorsalis lateralis. It separated into two or three finer twigs which ramified in the musculature and did not seem to emerge under the surface of the skin of the dorsal aspect of the tail.

The dorsolateral branches were larger and seemed to be constituted by a greater amount of fibers than those of the dorsomedial branches. The first dorsolateral branch of the coccygeal spinal nerve (N. spinalis coccygeus I) was joined by the dorsal branch of the last sacral spinal nerve. The conjoined trunk then traversed caudolaterally lying over the transverse process of the following coccygeal vertebra and united with the dorsolateral branch of the second coccygeal spinal nerve which extended to join the dorsolateral branch of the third coccygeal nerve and so on. This resulted in the formation of a well formed trunk which was augmented from the first to the middle of the tail and was named the dorsal coccygeal trunk (Fig. No. 15a; Plate No. 13: $Cy_1a - Cy_6a$; Cy').

The dorsal coccygeal trunk (Tr. coccygeus dorsalis) traversed caudolaterally, lying over the dorsal surface of the transverse processes of the coccygeal vertebra between the *Mm. intertransversarii caudae*, ventrally, and the *M. sacrococcygeus dorsalis lateralis*, dorsally (Fig. No. 15a; Plate No. 13: $C'y$). During its course it gave off distinctive muscular and cutaneous twigs for the innervation of these muscles. Some of these twigs, in most cases four to six grossly dissectable twigs, pierced the *M. sacrococcygeus*

dorsalis lateralis to reach the surface of the skin and were responsible for the innervation of the skin of the dorso-lateral aspect of the tail. However, the dorsal coccygeal trunk extended from the first coccygeal vertebra to the tip of the tail and during its course gave off a number of fine twigs, but it could not be checked grossly whether these emerged under the surface of the skin or not.

2. Ventral branches (Rami ventrales)

The ventral branches of the coccygeal spinal nerves were stronger than the dorsal branches. Each emerged from the intervertebral foramen. The first three to four ventral branches divided into medial and lateral branches. This division was not distinctive in the caudal series and, in this case, the ventral branches, after their emergence through the intervertebral foramen, traversed caudolaterally to join with the ventral branch of the following coccygeal spinal nerves, but they gave off a small twig which went into the M. sacrococcygeus ventralis medialis. However, where the division of the ventral branch was clearly marked into medial and lateral branches, the medial branches were smaller than the lateral branches and these traversed dorsolaterally under the M. sacrococcygeus ventralis lateralis and ramified into these muscles.

The lateral branch of the first coccygeal spinal nerve (N. spinalis coccygeus I) received contributory twigs from the ventral branch of the last sacral spinal nerve (N. spinalis sacrales IV). (Fig. No. 15b ; Plate No. 14: Cy₁b). It traversed caudolaterally to join the bulk of the ventral branch of the second coccygeal spinal nerve (N. spinalis coccygeus II) which, in turn, joined with the ventral branch of the third coccygeal spinal nerve (N. spinales coccygeus III) and so on, resulting in the formation of the ventral coccygeal trunk (Fig. No. 15b; Plate No. 14: Cy").

The ventral coccygeal trunk (Tr. coccygeus ventralis) traversed caudally, lying ventral to the transverse processes of the coccygeal vertebra and the M. intertransversari ventralis caudae extending from the first coccygeal vertebra to the tip of the tail, covered ventrally by the M. sacrococcygeus ventralis lateralis and accompanied by the ventrolateral coccygeal artery. During its course it gave off a number of muscular twigs for the innervation of the M. sacrococcygeus ventralis lateralis and M. sacrococcygeus ventralis medialis. There were five to six dissectable cutaneous twigs given off by these branches which perforated the M. sacrococcygeus ventralis lateralis to reach the ventrolateral aspect of the skin of the tail in which these finally ramified

(Plate No. 14: C"y). These were responsible for the innervation of the skin of the ventrolateral aspect of the tail. Though the ventral coccygeal trunk gave off a number of small fine twigs which took the same course taken by the twigs terminating as cutaneous twigs, but could not be traced to the surface of the skin.

IV. DISCUSSION

As stated earlier there is not much information available in the literature regarding the cutaneous nerves of the pig and for this reason, the present investigations had to be reviewed and discussed in the light of studies done on other domestic animals. However, all the available information in the present textbooks and literature about the cutaneous nerves of the domestic pig has been utilized.

All of the textbooks consulted (Barone, 1964; Ellenberger and Baum, 1943; Montane and Bourdelle, 1920; Sisson and Grossman, 1953) agree that in all the domestic animals the number of vertebrae present in a particular region determines the number of spinal nerves, in that particular region. All agree that the number of spinal nerves in the cervical region is always eight, while the number of spinal nerves in the thoracic, lumbar, sacral and coccygeal regions vary depending upon the number of vertebra present. The present investigator found, in his specimens, that there were seven cervical vertebrae in all the specimens; fourteen thoracic vertebrae in two cases, fifteen in seven cases, and sixteen in one case; six lumbar vertebrae were found in ten cases while one had five lumbar vertebrae; and there were four sacral segments in all the specimens; while the number of coccygeal vertebrae

was not counted though there were four to eight pairs of coccygeal spinal nerves. Out of eleven specimens dissected in two cases there were four pairs, in eight cases there were six pairs while one had eight pairs of coccygeal spinal nerves. Therefore, the number of spinal nerves found varied from 35 to 42 pairs - C₈ T₁₄₋₁₆, L₅₋₆, S₄, Cy₄₋₈. Montane and Bourdelle (1920) state that there are usually 38 to 41 pairs of spinal nerves - C₈, T₁₄ or 15, L₆ or 7, S₄, Cy₆₋₇, while Sisson and Grossman (1953) mention that there are eight cervical, commonly fourteen thoracic, seven lumbar and four sacral spinal nerves in the pig. Ellenberger and Baum (1943), state that the number of thoracic vertebrae varies from fourteen to seventeen and that of the lumbar vertebrae is usually seven. Therefore, it seems that except for the cervical and sacral regions, the number of spinal nerves are fairly variable, though the present investigator found that generally there are 39 pairs of spinal nerves - C₈, T₁₅, L₆, S₄, Cy₆.

The number of thoracic vertebrae did not seem to determine the reduction or increase in the number of lumbar vertebrae as it was noticed that while the number of thoracic vertebrae varied from fourteen to sixteen, the number of lumbar vertebrae was six in all but one case which had fifteen thoracic vertebrae but five lumbar vertebrae.

A. The Cervical Cutaneous Nerves

As in all the other domestic animals, there were eight pairs of cervical spinal nerves while the number of cervical vertebrae was seven. In the pig the dorsal branch of each cervical nerve was seen lying along with its corresponding vertebra; the dorsal branches emerging through the lateral vertebral foramen and the ventral branches emerging through the intervertebral foramen, except the first ventral branch which emerged through the intervertebral foramen of the atlas and, therefore, lay cranial to its corresponding cervical vertebra (Fig. No. 4, 5: c, b, C₈b).

Jankovic (1954) agrees that there are always eight pairs of cervical spinal nerves in the domestic pig. The present investigator found that, as in case of the dog (Miller et al. 1964), cattle (Schaller, 1956), and the horse (Barone, 1964, Sisson and Grossman, 1953), in the pig, as well, all the cervical spinal nerves did not give off cutaneous branches. Each cervical spinal nerve showed all the characteristics of a typical spinal nerve divided into dorsal and ventral branches, which further subdivided into medial and lateral branches. It had been seen that the dorsomedial branches terminated as the cutaneous branches for the innervation of the dorsal and dorsolateral aspect of the neck region while the dorsolateral

branches ramified in the muscles of the neck. It was seen that there were communicating branches between the dorsal branches of the fourth, fifth, and sixth cervical spinal nerves in all except two specimens. These communicating branches contributed to the formation of the dorsal cervical plexus (Fig. No. 4, 5: C_{2a'} - C_{7a'}) and, thus, concurred with Montane and Bourdelle (1920). A similar plexus is also present in the horse (Barone, 1964, Sisson and Grossman, 1953) while in cattle (Schaller, 1956) and in the dog (Miller et al, 1964) no such plexus is formed. In the present studies it was observed that in most of the cases the dorsomedial branches of the first and eighth cervical nerves did not terminate as cutaneous branches. It seems that the size of the dorsomedial branches reached its maximum in the third and fourth and then decreased progressively onwards and the dorsomedial branch of the eighth cervical nerve was very thin and fine and perhaps due to this reduction in size, did not reach the surface of the skin. The same seemed to be true with the dorsal branch of the first cervical nerve. Schaller (1956), investigated the cutaneous nerves of cattle and found that very rarely the dorsomedial branch of the eighth and dorsal branch of the first cervical nerve terminated as the cutaneous branches. In the horse Barone (1964)

and Sisson and Grossman (1953) state that though the dorsal branches of the seventh and eighth cervical nerves are very much reduced they terminate as cutaneous branches. In the case of the dog (Miller et al. (1964) states that the dorsal branches of the eighth cervical nerve may be absent. The present investigator found that, in the case of the pig, the dorsal and dorsolateral aspect of the skin of the neck region was generally innervated by the dorsomedial branches of the second to seventh cervical spinal nerves, the first and eighth terminating as cutaneous branches only in one case, though these were always present.

There were certain peculiarities regarding the emergence of the dorsal branches from the vertebral canal and these were found to be specific only in the domestic pig. It was seen that the dorsal branches of the cervical spinal nerves I to VIII emerged through the lateral vertebral foramen, present in all the cervical vertebrae (Fig. No. 5: C₁) and the dorsal branches emerged through these foramen instead of the intervertebral foramen, as is the case in other domestic animals. Nickel, Schummer and Seiferle (1961) agree that the dorsal branches of the cervical spinal nerves emerge through the lateral vertebral foramen in the pig, and through the intervertebral foramen in the other domestic animals.

This seems to be reasonable and logical as this additional foramen is present only in the domestic pig while there is no such foramen in the other domestic animals and, therefore, the dorsal branches have to emerge through the intervertebral foramen.

The ventral branches were seen to be much larger and stronger than the dorsal branches and had strong communicating branches with each other. It was found that the innervation of the skin of the lateral, ventrolateral and ventral aspect of the neck was by the cutaneous branches which were given off by the second, third, fourth, and fifth cervical nerves. Montane and Bourdelle (1920) agree that these branches have strong communicating branches leading into the formation of the ventral cervical plexus in the pig. Miller, et al. (1964) state that the cervical plexus is rarely formed in the dog, while, according to Barone (1964) and Sisson and Grossman (1953) in the horse the ventral cervical plexus is formed and this is also the case in cattle, according to Schaller (1956). However, the present investigator found that a ventral cervical plexus was formed in all cases except one, while in all the other specimens with the exception of one, there was never seen a communicating branch between the ventral branches of the third and fourth cervical nerves. There

were three types of communicating branches between all the ventral branches of the cervical spinal nerves except the first ($C_2 + C_3 + C_4 + C_5 + C_6 + C_7 + C_8$) (Plate No. 4). In seven cases, there were communicating branches between the second and third then the fourth, fifth, sixth, seventh and eighth ($C_2 + C_3; C_4 + C_5 + C_6 + C_7 + C_8$) (Fig. No. 2, 3, 4, 5; Plate No. 1 and 2). In two cases there were no communicating branches between the fourth and fifth cervical spinal nerves ($C_2 + C_3; C_4; C_5 + C_6 + C_7 + C_8$) (Plate No. 3). So, it was evident that a perfect cervical plexus was formed in only one case; in seven cases an incomplete cervical plexus was formed while in two cases the ventral cervical plexus was not formed. The distance at which these communications occurred varied from specimen to specimen except that the ventral branches of the second and third cervical nerve was fairly constant, nearly an inch or so after the emergence of the second cervical nerve.

The present investigator observed that the ventral branch of the second cervical nerve did not seem to have an independent course and it joined with the ventral branch of the third cervical nerve. This appears to be contrary to what has been observed in the other domestic animals. Because of this, in the case of the pig, the great auricular nerve

(N. auricularis magnus) and transverse cervical nerve (N. transversus cervicalis) did not arise from the ventral branch of the second cervical nerve, as such. They were given off from the conjoined trunk formed by the ventral branches of the second and third cervical nerves (Fig. No. 2, 3, 4, 5: A). But Montane and Bourdelle (1920) appear to disagree as they state that the great auricular nerve is given off by the ventral branch of the second cervical nerve. According to Miller, et al. (1964) in the dog; Barone (1964) and Sisson and Grossman (1953) in the horse; and Schaller (1956) in cattle; the great auricular and transverse cervical nerves arose from the ventral branch of the second cervical nerve. However, both of these branches terminated as cutaneous branches. The ventral branches of the rest of the cervical nerves further subdivided into medial and lateral branches (Fig. No. 3, 4, 5; Plate No. 3: C₃b' - C₅b' and C₅b"). The medial branches took a dorsal course to innervate the various muscles of the neck. The lateral branches took an oblique caudoventral course and divided into a number of fine, small twigs under the surface of the skin to ramify as cutaneous branches (Fig. No. 1: C₂₊₃b", C₄₊₅b"). It was observed that under the surface of the skin these branches extensively subdivided into fine, slender and long cutaneous branches and there appeared to be extensive overlapping of the areas

innervated by each of them (Fig. No. 1: C₂b" - C₅b"). The present investigator found that the innervation of the lateral, ventrolateral and ventral aspect of the skin of the neck was accomplished by the various cutaneous branches given off by the ventrolateral branches of the second, third, fourth, and, in two cases, by the fifth cervical nerves (Fig. No. 1: C₂b" - C₅b"). The ventral branch of the first did not give off a cutaneous branch while the ventral branches of the fifth, sixth, seventh, and eighth went into the formation of the brachial plexus. The same seems to be true in the case of the dog (Miller, et al., 1964); horse, Barone, 1964; Sisson and Grossman, 1953) and cattle (Schaller, 1956), though the pattern of branching and distribution seems to be quite different.

B. Thoracic Cutaneous Nerves

As stated earlier the number of thoracic spinal nerves varied depending upon the number of thoracic vertebrae, but the present investigator found that there were commonly fifteen pairs of thoracic spinal nerves in his specimens, though out of eleven specimens dissected, two had fourteen and one had sixteen pairs.

The present investigator found that the emergence of the thoracic spinal nerves was characteristic in the pig and

differed from that of the other domestic animals. It was observed that the thoracic spinal nerve did not emerge from the intervertebral foramen in the case of the pig, as has been reported for the dog (Miller, et al. 1964); horse (Barone, 1964) and (Sisson and Grossman, 1953); and cattle (Schaller, 1956). Each thoracic spinal nerve divided into dorsal and ventral branches which were seen to emerge through the foramen vertebrae lateralis dorsalis and foramen vertebrae lateralis ventralis of the corresponding thoracic vertebra (Fig. No. 11, 12: H). This is due to the fact that these two foramina are not present in other domestic animals, while they have been reported to be present in the thoracic vertebrae of the pig only by Nickel, et al. (1961). It appeared that because of the presence of these two foramina, the dorsal and ventral branches of the thoracic spinal nerves emerged through these foramina instead of through the intervertebral foramen. Therefore, it was observed that a particular thoracic spinal nerve was not seen lying caudal to its corresponding thoracic vertebra as is the case in all the other domestic animals, but each thoracic spinal nerve was seen lying along with the corresponding thoracic vertebra. The dorsal branches took an oblique dorsal course, while the ventral branches traversed caudoventrally to lie as intercostal nerves along with the posterior groove of the corresponding rib (Fig. No. 12: Ta', Ta" and Tb).

Each dorsal branch further subdivided into medial and lateral branches and both of these terminated as cutaneous branches on the dorsal and dorsolateral aspect of the thoracic region as is the case in cattle (Schaller, 1956). (Fig. No. 7, 9, 13 ; Plate No. 5, 6, 7: Ta' and Ta"). The dorsomedial branches in the dog (Miller, et al., 1964) and horse (Sisson and Grossman, 1953) do not terminate as cutaneous branches and the innervation of the dorsolateral aspect of the skin of the thoracic region is by the dorsolateral branches only. Montane and Bourdelle (1920), in their brief description of the thoracic nerves of the pig, mention that the superior (or dorsal) branches of these nerves terminate in the dorsospinal muscles while the inferior (or ventral) branches continue as the intercostal nerves. It was seen that both the dorsomedial and dorsolateral branches gave off a number of muscular branches for the innervation of the muscles of the dorsal aspect of the thoracic region but finally these perforated through the musculature to terminate as cutaneous branches. It had been further observed that the dorsolateral branches under the surface of the skin further subdivided into two cutaneous branches - one took an dorsomedial course and the other traversed in a dorsolateral direction (Fig. No. 7, 9, 10, 13; Plate No. 5: Ta"). But it was seen that the twigs from the

dorsolateral branches taking a dorsomedial course alternated with the dorsomedial branches and never traversed to these branches. This pattern seems to be in accord with the pattern followed by these branches in the lumbar region and is same as is the case in cattle (Arnold and Kitchell, 1957). It was further observed that the course followed by the dorsomedial branches of the first ten or eleven thoracic spinal nerves was conspicuously different than these of the last four or five thoracic spinal nerves (Fig. No.

Plate No. 7: T₅a' to T₉a' and T₁₀a' to T₁₅a'). It was seen that the first ten or eleven branches took an oblique, dorsal ascending course lying over the mammillary process of the following thoracic vertebrae and the M. multifidus dorsi, while the last four or five curved around and under the mammillary process and then lay embedded in the M. multifidus dorsi, in their dorsal ascending course (Fig. No.

; Plate No. 7: T₅a' - T₉a'; T₁₀a' - T₁₅a'). This appears to be due to the fact that the mammillary processes of the first ten or eleven thoracic vertebrae are not very prominent and well developed but, as their development progressively increases to be maximum in the last four or five thoracic vertebrae, the dorsomedial branches have to change their course with the changed anatomical relationship. Therefore, the dorsomedial branches of the last four or five

thoracic spinal nerves had to curve around lying under the curve of the mammillary processes and the *M. multifidus dorsi* to reach the undersurface of the skin.

The ventral branches continued as intercostal nerves and these gave off mainly three cutaneous branches which were similar to those in man (Davies, 1932). Near the middle of the rib each intercostal nerve gave off a perforating branch which further subdivided into lateral cutaneous branches and distal lateral cutaneous branches while the main trunk continued to terminate as the ventral cutaneous branch (Fig. No. 6, 8, 9, 10, 11; Plate No. 5 and 8: $T_4b'' - T_{14}b''$: 5, 8, 9 and 10: Tb''' , Tb'''' and Tb'). It seems to be similar to man in which, according to Davies (1932), the intercostal nerve terminates as the anterior cutaneous branch while in its course it gives off lateral and collateral cutaneous branches. This appears to be due to the embryological closeness between the pig and man, as Sinclair (1937) states, the pattern of innervation in the pig is exactly the same as that in man. It had been observed that the perforating branches of the first two or three intercostal nerves were longest and most well developed as compared to succeeding perforating branches. This is in conformity with Montane and Bourdelle (1920).

The pattern of branching of the intercostal nerves seems to be same in the case of the dog (Miller, et al, 1964), cattle (Schaller, 1956), and the horse (Sisson and Grossman, 1953).

C. The Lumbar Cutaneous Nerves

The number of lumbar spinal nerves was found to be dependent upon the number of lumbar vertebrae present. The present investigator found that there were six lumbar vertebrae and therefore six pairs of lumbar spinal nerves, in ten out of eleven specimens dissected. This seems to be in contrast with the textbooks consulted such as Ellenberger and Baum (1943), Montane and Bourdelle (1920), Nickel, et al. (1961) and Sisson and Grossman (1953) who all agree that there are usually seven pairs of thoracic spinal nerves with a reduction to six, though the number is variable from five to seven pairs. The work of Reimers (1913) confirms the presence of seven pairs of lumbar spinal nerves, in general, with a reduction to six. However, Uchida (1929) found six pairs of lumbar sympathetic ganglia. In the opinion of the present investigator, these were equated with the number of lumbar vertebrae present. As had been stated earlier it did not seem that the number of thoracic vertebrae present had any relation with the reduction or increase in the number of lumbar vertebrae

as, irrespective of the frequent variation in the number of thoracic vertebrae in present studies, the number of lumbar vertebrae stayed constant in all but one specimen.

As in other domestic animals, the lumbar spinal nerves left the spinal canal through the intervertebral foramen as the additional dorsal lateral vertebral and ventral lateral vertebral foramina were lost in the lumbar region and, therefore, each lumbar spinal nerve was seen lying caudal to the corresponding lumbar vertebrae, as is the case in all the other domestic animals (Fig. No. 14: La' and Lb').

However, after emergence, each lumbar spinal nerve divided into dorsal and ventral branches. The dorsal branches had a similar course and branching as that of the dorsal branches of the thoracic spinal nerves. As the mammillary processes were seen to be most developed in the lumbar region, the dorsomedial branches had to curve around and traverse underneath the mammillary process of the following lumbar vertebrae and the M. multifidus dorsi to reach the surface of the skin (Fig. No. 7: M ; Plate No. 11: L₁a' - L₅a'). The dorsolateral branches also pursued a similar course as that of the dorsolateral branches of the thoracic spinal nerves except that the last three or four were seen embedded in the M. longissimus dorsi and had a progressively increasing oblique course (Fig. No. 7, 8, 9, 10; Plate No. 5, 6, 9 and

11: L₁a" - L₅a"). This, in the opinion of the present investigator, is due to the fact that as the M. longissimus dorsi increased in its mass in the lumbar region, the last three to four dorsolateral branches came to lie in this muscle rather than under it. The progressive increase in the obliquity of the spinal nerves from thoracic to sacral nerves is due to the established fact that the growth of the vertebral column is much more rapid than that of the spinal cord. To meet this situation and to emerge through the foramen, spinal nerves stretch and this results in the progressive obliquity of the spinal nerves which is most marked in the lumbar and sacral regions. The same is true in all the other domestic animals.

The ventral branches of the lumbar spinal nerves were seen to be responsible for the innervation of the skin of the flank region along with the ventral branch of the last thoracic spinal nerve. The ventral branches were not very closely studied regarding their intercommunications, though these were investigated in relation to the cutaneous innervation of this region as it was thought to be beyond the scope of the present investigations. The N. iliohypogastric divided into cranial and caudal branches; the cranial being the superficial one which emerged through the M. obliquus abdominis externus to appear under the surface of the skin of the middle

abdominal wall (Fig. No. 9, 10, 13,14; Plate No. 12: L₁b' and L₁b"). Similarly, N. inguinalis also divided into cranial and caudal branches, which had the same course as that of the corresponding branches of first lumbar (Plate No. 12: L₂b' and L₂b"). The present investigator found that in all specimens except one, the N. cutaneous femoris lateralis was derived from the main trunk of the ventral branch of the fourth lumbar spinal nerve; while the ventral branch of the third always gave off contributory branches for its formation. (Fig. No. 14; F ; Plate No. 12: L₃b, L₄b: F). In one case, which had five pairs of lumbar spinal nerves, the N. cutaneous femoris lateralis was formed by the ventral branch of the third lumbar spinal nerve; while the second gave off contributory branches. It seems to be in disagreement with Montane and Bourdelle (1920) as, according to these authors, it arises from the ventral branches of the fourth and fifth lumbar spinal nerves. Reimers (1913) found in his work that this nerve was given off by the ventral branch of the fifth lumbar spinal nerve, while it received a contributory branch from the ventral branch of the sixth lumbar nerve. But Bosa (1965) found that in most cases (eleven out of fifteen) the N. cutaneous femoris lateralis arose from the ventral branch of the fourth, having a contributory branch from the ventral branch of the

third lumbar spinal nerve. In the opinion of the present investigator a difference in the number of lumbar spinal nerves led to this difference in the formation of the N. cutaneous femoris lateralis (Montane and Bourdelle, 1920; and Reimers, 1913 had found seven pairs of lumbar spinal nerves, while the present investigator found six pairs of lumbar spinal nerves).

Intercommunicating branches had been found between the ventral branches of the second, third, fourth, fifth and sixth lumbar spinal nerves. These contributed in the formation of the lumbosacral plexus. The ventral branches of the fifth and sixth lumbar spinal nerves were entirely associated in the formation of the lumbosacral plexus and did not give off cutaneous branches for the innervation of the area under consideration (Fig. No. 14: L₅ ; Plate No. 12: L₅b, L₆b).

In the dog, the N. cutaneous femoris lateralis is derived from the fourth, having branches from the third and fifth lumbar spinal nerves (Miller, et al, 1964); in the horse from the third with contributory branches from the fourth lumbar spinal nerves (Barone, 1964 and Sisson and Grossman, 1953) and in cattle mainly from the fourth with branches from the ventral branch of the third lumbar spinal nerve (Reimers, 1913).

D. The Sacral Cutaneous Nerves

In all the specimens dissected, there were four pairs of sacral spinal nerves and all the textbooks agree that the number of sacral spinal nerves is fairly constant as is the number of sacral segments. Montane and Bourdelle (1920), Jankovic (1954), Reimers (1913) and others all agree that there are four pairs of sacral spinal nerves in the domestic pig.

Each sacral spinal nerve had all the characteristics of a typical spinal nerve dividing into dorsal and ventral branches. It was observed that the dorsal branches further subdivided into dorsomedial and dorsolateral branches. But, as had been observed in the thoracic and lumbar regions, the dorsomedial branches did not emerge under the surface of the skin but terminated in the musculature. This was, perhaps, due to the fact that the dorsal branches of the sacral spinal nerves were very much reduced in size. It was seen to be particularly true for the dorsomedial branches which consisted of only a few fibres and took a caudal course to ramify in the musculature. However, fine, slender and long dorsolateral branches traversed caudally and emerged over the gluteal region lying far away from their foramen of exit. The last sacral spinal nerve did not emerge under the surface

of the skin as it traversed to join with the dorsal branch of the first coccygeal nerve to form the dorsal coccygeal trunk. The size of these sacral spinal nerves decreased from the first to the last as is the case in dog (Miller, et al, 1964); cattle (Schaller, 1956); horse (Barone, 1964 and Sisson and Grossman, 1953) and in the pig (Reiners, 1913). Reiners (1913) seems to agree completely with the present investigator regarding the branching, distribution and ramification of the dorsolateral branches of the sacral spinal nerves.

The ventral branches, as stated under "Results," were found to be associated with the formation of the lumbosacral plexus and in the present investigation the cutaneous nerves arising from the lumbosacral plexus was not studied except when necessary. In all the specimens dissected, the N. cutaneous femoris caudalis arose from the ventral branch of the second sacral spinal nerve while it always had contributory branches from the third and rarely from first. This seems to be in agreement with Bosa (1965) and Reiners (1913). (Fig. No. 14: S₃b ; Plate No. 12: S₂ and S₃).

E. The Coccygeal Cutaneous Nerves

As had been stated earlier, the number of coccygeal spinal nerves varied from four to eight pairs, though the present investigator found that commonly there were six pairs of coccygeal spinal nerves (Fig. No. 15a; Plate No. 13: Cy₁a - Cy₆a). Montane and Bourdelle (1920) found five pairs of coccygeal spinal nerves. However, though being very small, these exhibited all the typical characteristics of a spinal nerve. As the spinal cord does not extend up to the coccygeal region but as these nerves have to innervate the skin up to the tip of the tail, both the dorsal as well as ventral branches of the coccygeal spinal nerves united with the succeeding dorsal and ventral branches, so as to reinforce and combine their fibres and constituted the dorsal and ventral coccygeal trunks (Fig. No. 15b; Plate No. 13: Cy'; 14: Cy"). These dorsal and ventral coccygeal trunks then extended to the tip of the tail and, during their course, gave off a number of muscular as well as cutaneous twigs for the innervation of the muscles and skin of the tail.

VI. SUMMARY AND CONCLUSIONS

The general pattern of cutaneous innervation of the cervical, thoracic, lumbar, sacral, and coccygeal regions of the domestic pig, *Sus scrofa domesticus*, was investigated. The studies were carried out on eleven specimens, seven females and four males, by way of gross dissections only. These were of various breeds and ages. All the cutaneous branches arising from the spinal nerves of these regions were studied in detail regarding their origin, course, intercommunications, branching, distribution, and approximate area of ramification on the surface of the skin. Essentially three methods of approach were followed to expose these nerves:

1. Centripetal - The cutaneous branches were picked up on the surface of the skin and then were traced back to their place of origin.
2. Centrifugal - The main branches of the spinal nerves were picked up as soon as these emerged from the spinal canal and then their main branches were traced to their area of ramification.
3. Medial approach - This method was used to study the course and the termination of the intercostal nerves.

A. Cervical Cutaneous Nerves (Nn. cutanei cervicales)

In all the specimens dissected there were eight pairs of Nn. spinales cervicales. In all cases, like a typical spinal nerve, each divided into dorsal and ventral branches, which further subdivided into medial and lateral branches. The innervation of the skin of the cervical regions was accomplished by the various cutaneous branches of the second, third, fourth and fifth Nn. spinales cervicales. But there were many variations in their mode of branching and distribution.

In all the specimens dissected, the dorsal branch of the first cervical nerve was not seen to divide into medial and lateral branches and, in most of the cases, did not terminate as the cutaneous branch. The medial branches of the Ramus dorsalis Nn. spinales cervicales II to VII terminated as the cutaneous branches and were responsible for the innervation of the skin of the dorsal and dorsolateral aspects of the cervical region. In eight out of ten specimens dissected, it had been observed that the medial branches of the fourth, fifth and sixth Ramus dorsalis, gave off intercommunicating branches which contributed to the formation of the dorsal cervical plexus (plexus cervicalis dorsalis superficialis). In two cases, no such communicating

branches were seen. The dorsal branch of the eighth cervical nerve was found to be very slender, and it did not seem to divide into medial and lateral branches. In more of the specimens it was seen terminating as a cutaneous branch. The lateral branches of the Rami dorsales, in all the specimens, were seen ramifying in the muscles of the neck and in no case did these terminate as cutaneous branches.

The ventral branches of the cervical nerves (Rami ventrales Nn. spinales cervicales) are more developed than the dorsal branches. These were found to be greatly variable in their branching and distribution. The ventral branch of the first cervical nerve was not found to terminate as a cutaneous branch. In all the cases, the N. auricularis magnus and N. transversus cervicalis arose from the conjoined trunk formed by the ventral branches of the second and third cervical nerves. These received contributory branches from the dorsal branch of the N. spinalis accessorius.

In all the specimens dissected, except for one, there was formation of the ventral cervical plexus. Mainly, three types of arrangement was seen for the formation of this plexus.

In one case, there were seen communicating branches between $C_2 + C_3 + C_4 + C_5 + C_6 + C_7 + C_8$.

In seven cases, there were seen communicating branches between $C_2 + C_3$; $C_4 + C_5 + C_6 + C_7 + C_8$.

In two cases, there were seen communicating branches between $C_2 + C_3$; C_4 ; $C_5 + C_6 + C_7 + C_8$.

The intercommunicating branches were given off by the lateral branches of the Rami ventrales and these branches further subdivided into a number of cutaneous branches which constituted the innervation of the skin of the lateral, ventrolateral, and ventral aspects of the cervical region.

The medial branches of the Rami ventrales ramified in the muscles of the neck region and did not give off any cutaneous branches.

In all these cases, the external thoracic nerve (N. thoracalis lateralis) was seen to be constituted by ventral branches of $C_8 + C_1$; while the phrenic nerve (N. phrenicus) was constituted by the branches from the Rami ventrales of $C_5 + C_6$.

B. Thoracic Cutaneous Nerves (Nn. cutanei thoracici)

The innervation of the skin of the thoracic region was by the cutaneous branches given off by the thoracic spinal nerves. The number of thoracic spinal nerves varied from fourteen to sixteen pairs, corresponding to the number of

the thoracic vertebrae. In ten specimens, the number of thoracic spinal nerves observed was as follows:

Sixteen pairs - one case

Fifteen pairs - seven cases

Fourteen pairs - two cases

These lay caudal to the corresponding thoracic vertebrae. Each thoracic spinal nerve divided into dorsal and ventral branches which emerged from the vertebral canal through the foramen vertebrales laterales dorsales and foramen vertebrales laterales ventrales, respectively.

The dorsal branch further subdivided into medial and lateral branches. Both terminated as cutaneous branches resulting in the innervation of the skin of dorsal and proximal one-third of the dorsolateral aspect of the thoracic region. The medial branches, followed essentially, two courses as the course followed by the first ten or eleven branches was different than that followed by the last five or six branches. The first ten or eleven branches ascended obliquely, dorsally lying over the M. multifidus dorsi and mammillary process, while the last five or six branches curved under the mammillary process of the following thoracic vertebra lying in the M. multifidus dorsi, close to the spinous process of the following vertebra. These branches ultimately emerged through the supraspinous ligament to spread out on the skin of the dorsolateral aspect of thoracic region.

The lateral branches of the Rami dorsales had a fairly constant course and distribution, except in two cases, where there were two lateral branches given off by the Rami dorsales of the second, third and fourth thoracic spinal nerve. The first three or four lateral branches perforated through the scapular cartilage and the M. trapezius pars thoracis to appear on the surface of the skin. These had an almost similar course except that of perforating through different muscles at different levels to appear on the skin. Essentially, these had three types of course depending upon their relationship with the thoracic musculature.

Soon after their emergence through the musculature, each lateral branch subdivided into two branches - one taking a dorsal course, while the other traversed latero-ventrally. These were responsible for the innervation of the proximal one-third of the dorsolateral aspect of the thoracic region.

The ventral branches continued along the posterior border of the corresponding rib as intercostal nerves (Nn. intercostales). During its course, each intercostal nerve gave off the following cutaneous branches:

- a. Perforating branches (Rami perforantes) - gave off two cutaneous branches.

1. Lateral cutaneous branches - innervating the skin of the lateral aspect of the thoracic and part of the abdominal wall.
2. Distal lateral cutaneous branches - innervating the ventrolateral aspect of the thoracic and abdominal wall.

b. Ventral cutaneous branches These were found to be the termination of the intercostal nerves and emerged on the side of the mid-ventral line. The course followed by the intercostal nerves of the sternal ribs was different than those of the asternal ribs, as they terminated as the ventral cutaneous branches. These branches were mainly responsible for the innervation of the mammary gland in the female and the skin of the penis and adjoining regions in the male. The aggregate of all these branches innervated the skin of the ventral aspect of the thoracic region and abdominal wall.

The pattern of branching and area of ramification of various branches of thoracic spinal nerves:

		1	innervate the skin of the dorsal aspect of the thoracic region
	MEDIAL BRANCH		
	DORSAL BRANCH	2	
		1	innervate the skin of the dorso-lateral aspect of the thoracic region
	LATERAL BRANCH	2	
		3	
THORACIC SPINAL NERVES			
	VENTRAL BRANCH	1	innervate the lateral aspect of thorax
	1. Lateral Cutaneous Branch		
a. Perforating Branch		2	
	2. Distal Lateral Cutaneous Branch		Innervate the skin of the ventro-lateral aspect
	1 Sternal		
b. Ventral Cutaneous Branch			Innervate the skin of the ventral aspect of the thoracic region and part of the abdominal region
	2 Asternal		

C. Lumbar Cutaneous Nerves (Mn. cutanei lumbales)

In all the specimens dissected, except for one, there were six pairs of lumbar spinal nerves and one had five pairs. Each lumbar spinal nerve emerged through the intervertebral foramen, lying caudal to the corresponding lumbar vertebra. After its emergence, each divided into dorsal and ventral branches. The dorsal branches traversed to lie over the dorsal surface of the transverse process of the following vertebra and, at the cranial edge of its mammillary process, further subdivided into medial and lateral branches. The medial branches curved around the mammillary process of the following vertebra and then ascended dorsally, embedded in the *M. multifidus dorsi* to reach the surface of the skin. These were responsible for the innervation of the dorsal and dorsolateral aspects of the lumbar region. The dorsomedial branches of the last two lumbar spinal nerves were distributed over the rump region. The lateral branches of the *Rami dorsalis* were much stronger and oblique in their course than the corresponding branches of the thoracic spinal nerves. Moreover, the last three were found to be embedded in the *M. longissimus dorsi* and took a curved, oblique, caudal turn. The last two emerged to lie superficially over the *M. gluteobiceps* below the tuber coxae and finally spread out on

the surface of the skin of the rump region. Before their ramification, these branches usually broke up into a number of small twigs.

The first two ventral branches divided into cranial and caudal branches.

- | | | |
|----------------|---------|--|
| | Cranial | - superficial, ramified in the skin of the middle of abdominal wall |
| L ₁ | Caudal | - traversed deeply in the musculature to reach the skin of the ventral abdominal wall and mammary glands |
| | Cranial | - same course as that of L ₁ , lying caudal to it |
| L ₂ | Caudal | - same course as that of L ₁ , lying caudal to it |

In all these cases the N. cutaneus femoria lateralis arose from the ventral branch of the fourth lumbar spinal nerve, though it always received a contributory branch from the ventral branch of the third lumbar spinal nerve. Only in one case was it formed by the ventral branches of the second and third lumbar spinal nerves, and this specimen had five pairs of lumbar spinal nerves. At the level of the subiliac lymph node, it divided into two branches, which further subdivided into two and were found to be responsible for the innervation of the skin of the region of the plica and the medial and lateral aspects of the stifle joint.

The ventral branches of the fifth and sixth lumbar spinal nerves contributed in the formation of the lumbosacral plexus

(Plexus lumbosacralis) and did not give off any cutaneous branches for the regions under consideration in the present studies.

D. Sacral Cutaneous Nerves (Mn. cutanei sacrales)

In all the specimens dissected there were four pairs of sacral spinal nerves. Their dorsal branches left the vertebral canal through the dorsal sacral foramen. The dorsal branches were very slender, but long. Each divided into a medial and lateral branch except for the dorsal branch of the fourth sacral spinal nerve which was found to be the smallest of all and it traversed caudally to join the dorsal branch of the first coccygeal spinal nerve. The medial branches of the Rami dorsalis were very slender and traversed a short distance caudally to join each other. The lateral branch of the first sacral spinal nerve was seen to be the longest and most well developed as compared to the others. It ascended dorsally then took an oblique caudal course along with the sacrosciatic ligaments to finally appear superficially over the M. gluteobiceps and ramified in the skin of the rump region as far as the lateral aspect of the thigh. The lateral branches of the second and third sacral spinal nerves followed a similar course as that of the first,

lying caudal to it, and ramified in the same region. The third, however, was seen to be very small, did not traverse much caudally, and ramified in the skin cranial to the anal region.

The ventral branches were much stronger than the dorsal ones and, in all cases, were seen to have intercommunicating branches. The ventral branch of the first sacral spinal nerve, in all cases joined the ventral branch of the last lumbar spinal nerve. The major portion of the ventral branch of the second spinal nerve joined with the first sacral spinal nerve to help in the formation of the lumbosacral plexus. The ventral branches of the second and third sacral spinal nerves, in all the specimens studied, joined together to give rise to the N. caudalis femoris lateralis, which finally terminated as cutaneous branches innervating the anal region and part of the perinium. The perineal nerves arose from the pudendal nerve and were responsible for the innervation of the skin of the perinial region and mammary glands in females, and that of the scrotal region in males. The ventral branch of the fourth sacral spinal nerve was seen to be the smallest and it traversed caudally to join the ventral branch of the first coccygeal spinal nerve and helped in the formation of the ventral coccygeal trunk (Truncus coccygeus ventralis).

E. Coccygeal Cutaneous Nerves (Mn. cutanei coccygei)

The innervation of the skin of the tail, dorsal and ventral aspects was accomplished by a number of cutaneous branches which were given off by the dorsal coccygeal trunk (Truncus coccygeus dorsalis) and ventral coccygeal trunk (Truncus coccygeus ventralis), respectively. The number of coccygeal spinal nerves varied from four to eight pairs, though it was seen that in most of the cases the number of coccygeal spinal nerves was six pairs.

Four pairs - 2 cases

Six pairs - 8 cases

Eight pairs - 1 case

Like a typical spinal nerve, each coccygeal nerve was seen lying caudal to the corresponding coccygeal vertebra and divided into dorsal and ventral branches. However, the further subdivision of these into medial and lateral branches was not distinct in all the spinal nerves, except in the first three or four pairs of coccygeal spinal nerves. In these, the medial branches were very slender and traversed dorsally to ramify in the musculature. The lateral branches of the first three or four, and the dorsal branches of the last three or four, coccygeal spinal nerves traversed caudally and joined each other to form the dorsal coccygeal trunk.

This trunk traversed to the tip of the tail and, during its course, gave off a number of small fine twigs which were responsible for the innervation of the various muscles of the dorsal aspect of the tail and the skin of this area. Only four to six twigs could be traced to the surface of the skin.

The ventral branches of the coccygeal spinal nerves had an identical course and branching as that of the dorsal branches and resulted in the formation of the ventral coccygeal trunk which stretched to the tip of the tail, ventrally. During its course it passed off a number of fine muscular and cutaneous twigs for the innervation of the muscles and skin of the ventral aspect of tail.

VII. BIBLIOGRAPHY

- Arnold, J. P. and Kitchell, R. L. 1957. Experimental studies of the innervation of the abdominal wall of cattle. *American Journal of Veterinary Research* 18:229-240.
- Barone, R. 1964. Anatomie des équidés domestiques. Tome Troisième. Laboratoire D'Anatomie, Ecole Nationale Veterinaire, Lyon, France.
- Barone, R. and Chayer, R. 1950. Essais d'interpretation anatomique des anésthésies rachidiennes - chez le cheval et le Boeuf. *Revue de Médecine Vétérinaire* 101:27-42.
- Barone, R. and Schellenberg, P. 1951. The cutaneous nerves of the forelegs of horses. *Revue de Médecine Vétérinaire* 102:672-691.
- Baum, H. and Zietzschmann, O. 1936. Handbuch der Anatomie des Hundes. Band I. Skellett - und Muskelsystem. Paul Parey, Berlin, Germany.
- Bernhard, P. 1962. Beitrag zur vergleichenden des Vegetativen nervus systems in Bereich der Beckenhöhle der Fleischfresser, insbesondere des Hundes und der Katze. Vet. Dissertation. Library, University of Leipzig, Leipzig, Germany.
- Bolk, L. 1898-1899. Die segmental Differenzierung des Menschlichen Rumpfes und seiner Extremitäten. I. Morphologisches Jahrbuch, 25:465-543.
- Bosa, Y. M. 1965. Somatic and autonomic nerves of the lumbar and pelvic regions of the domestic pig. Unpublished M.S. thesis. Library, Iowa State University of Science and Technology, Ames, Iowa.
- Chauveau, A. and Arloing, S. 1902. The comparative anatomy of the domestic animals. 2nd edition. Appleton, New York, New York.
- Davies, F., Gladstone, R. J. and Stibbe, E. P. 1932. The anatomy of intercostal nerves. *Journal of Anatomy* 66:323-333.

- Dózsa, I. 1939. Peripheral nervous system of domestic animals. Thesis. Budapest, Hungary. pp. 34. Original not available; cited in Index Veterinarius 8:102, 1940.
- Dusser de Barenne, J. G. 1911. Die segmentare Strychnin Vergiftung der dorsalen Rückenmarks Mechanismen; ein Beitrag zur dermatomerie der hinteren Extremitäten des Hundes. Folia Neurobiologie 5:342-359.
- Ellenberger, W. and Baum, H. 1891. Systematische und topographische Anatomie des Hundes. Paul Parey, Berlin, Germany.
- Ellenberger, W. and Baum, H. 1943. Handbuch der Vergleichenden Anatomie der Haustiere. 18th edition. Springer Verlag, Berlin, Germany.
- Farquharson, J. 1940. Paravertebral lumbar anaesthesia in bovine species. American Veterinary Medical Association Journal 97:54-57.
- Goller, H. 1959. Vergleichende Rückenmarktopographie unserer Haustiere. Tierärztliche Umschau 14:107-110.
- Grau, H. 1935. The innervation of the skin of the limbs of horses. (translated title). Archiv für Wissenschaftliche und praktische Tierheilkunde 69:96-116.
- Grau, H. 1937. Innervation of skin and cutaneous muscular system of horses. (translated title). Archiv für Wissenschaftliche und praktische Tierheilkund 71:471-488.
- Havelka, F. 1928. Plexus lumbosacralis v psa. Vysoka škola Veterinární Biologické Spisy 7:1-40.
- Hekmatpanah, J. 1961. Organization of tactile dermatomes, C₁ through L₄ in cat. Journal of Neurophysiology 24:129-140.
- Hopkins, G. S. 1935. The correlation of anatomy and epidural anaesthesia in domestic animals. Cornell Veterinarian 25:263-270.
- Hughes, H. V. 1960. The skin of the dog. British Veterinary Journal 116:340-349.

- Jankovic, Z. K. 1954. Das Rückenmark, die Rückenmarkshüllen, ihre Zwischenräume und ihre topographie bei den Schweinen. Original not available; cited in Goller, H. 1959. Vergleichende Rückenmarktopographie unserer Haustiere. Tierärztliche Umschau 14:109.
- Koch, T. 1954. Innervation of the abdominal wall of the ox. (Translated title) Monatshefte für Veterinärmedizin 9:541-544.
- Kuhn, R. A. 1953. Organization of tactile dermatomes in cat and monkey. Journal of Neurophysiology 16:169-182.
- Leutert, Gerald. 1963. Die anatomischen Nomenklaturen von Basel. Jena, Germany.
- May, N. D. S. 1964. The anatomy of the sheep. 2nd edition. University of Queensland Press, St. Lucia, Brisbane, Queensland.
- Miller, Malcolm, E., Christensen, George, C., and Evans, Howard, E. 1964. Anatomy of the dog. W. B. Saunders Co., Philadelphia, Pennsylvania.
- Montané, L. and Bourdelle, E. 1920. Anatomie Regionale des Animaux Domestiques. Volume 4. Balliere et Fils, Paris, France.
- Nickel, R., Schummer, A. and Seiferle, E. 1961. Lehrbuch der Anatomie der Haustiere. Band I. Bewegungsapparat. Paul Parey, Berlin, Germany.
- Patten, Bradley, M. 1948. The embryology of the pig. 3rd edition. New York, New York, McGraw-Hill Book Company, Inc.
- Polyakov, V. A. 1959. Innervation of the muscles and skin of the forelimbs in Karakul sheep and Uzbek goats. (translated title). Akademii nauk Uzbekskoi Doklady 9:56-59.
- Reimers, H. 1913. Der Plexus lumbalis und sacralis des Rindes und Schweines. Inaugural Dissertation. Library, University of Leipzig, Leipzig, Germany.

- Rzhantisyna, I. S. 1958. Innervation of the different areas of skin in the domestic animals. (translated title). Trudy Troitskogo Veterinarnogo instituta 6:3-17.
- Schaller, O. 1956. Die periphere sensible Innervation der Haut am Rumpfe des Rindes. Wiener Tierärztliche Monatsschrift 43:346-368, 534-561.
- Schaller, O. 1965. Einige Besonderheiten der Rami dorsales nervosum cervicalium. Zentralblatt für Veterinärmedizin 6:549-552.
- Schneider, J. and Zintzsch, I. 1962. Die Leitungsanästhesie an den Extremitäten des Schweines. Zentralblatt für Veterinärmedizin 9:59-74.
- Schreiber, J. and Schaller, O. 1954. Anatomische Studien über die Extradurale Anästhesie bei Rind und Hund. Wiener Tierärztliche Monatsschrift 41:385-436.
- Seiferle, E. 1939. Topography of spinal cord in cattle and horse. (translated title). Zeitschrift für Anatomie 110:371-384.
- Sinclair, John, G. 1937. Anatomy of foetal pig. Collegiate Press, Ames, Iowa.
- Sisson, S. and Grossman, J. E. 1953. Anatomy of the domestic animals. W. B. Saunders Co., Philadelphia, Pennsylvania.
- Sussdorf, Von, H. 1889. Die Verteilung der Arterien und Nerven an Hund und Fuss der Haussäugetiere. Festschrift zum 25. jährigen Reg. Jubiläum des Königs Karl Von Württemberg, 1-39, Verlag Kohlhammer, Stuttgart, Germany.
- Thiel, G. 1941. Topography of the spinal cord of the dog. (translated title). Inaugural Dissertation. Hannover. Cited in Goller, H. 1959. Vergleichende Rückenmark-topographie unserer Haustiere 14:109.
- Uchida, Svemasa. 1929. Morphologische Studien über das Sympathischen nerven system des Schweines (Sus-asiaticus). II. Mitteilung. Brust-und Bauchteil. Anatomical Institute, Imperial University, Kyoto, Japan.

Walter, P. 1959. Die Innervation Flankengegend des Rindes. Tierärztliche Umschau 14:302-304.

VIII. ACKNOWLEDGEMENTS

The author expresses profound gratitude to his major professor, Dr. R. Getty, whose privileged guidance and counsel full of encouragement and constructive criticism is very deeply appreciated.

The author also expresses gratitude to the members of his graduate committee, namely, Dr. M. A. Emmerson, Dr. B. H. Skold and Dr. R. Bryan.

All of the excellent photographs and illustrative drawings were done by Dr. Daniel J. Hillmann and, the author, wishes to extend a special word of gratitude to Dr. Hillmann for his relentless offer of time, cooperation and understanding during the entire study.

Gratitude is expressed to Dr. N. G. Ghoshal whose help in translating the German articles cited in this thesis and encouragement during the investigations, is much appreciated. The author expresses his thanks to all the staff members of the Department of Anatomy who have been very cooperative and understanding.

Partial financial support was received from the Veterinary Medical Research Institute of Iowa State University which is acknowledged with appreciation.

Acceptance of the author by the Graduate College at Iowa State University of Science and Technology is acknowledged with deep appreciation and is considered as an appreciable act of good will.

The author wishes to express his indebtedness to his father and brother, who were instrumental in the authors studies abroad. The author is highly indebted to his brother, Madan Gandhi, who took the family's responsibilities and kept the authors morale high by regular communications.

153a

IX. APPENDIX A

Plate No. 1. Right lateral view of the cervical region showing the common pattern of branching, communication and disposition of the cervical nerves

a	M. trapezius pars cervicalis
c	M. serratus ventralis cervicis
d	M. scalenus medius
e	M. intertransversalis dorsalis
f	M. intertransversalis ventralis
C ₂ b, C ₄ b, C ₆ b, C ₈ b	Rami ventrales Nn. spinales cervicales II to VIII
C ₃ b'	Medial branch of Ramus ventralis N. spinalis cervicalis III
C ₅ b''	Lateral branch of Ramus ventralis N. spinalis cervicalis V
XI	N. spinalis accessorius

Plate No. 2. Left lateral view of the cervical region showing the common type of arrangement and distribution of the cervical nerves

a	M. trapezius pars cervicalis
b	M. rhomboideus cervicis
c	M. serratus ventralis cervicis
d	M. scalenus medius
f	M. intertransversalis ventralis
C ₂ b'', C ₄ b'', C ₅ b''	Lateral branches of Rami ventrales Nn. spinales cervicales II to V
C ₆ b, C ₈	Rami ventrales Nn. spinales cervicales VI to VIII
XI''	Ramus dorsalis N. spinalis accessorius

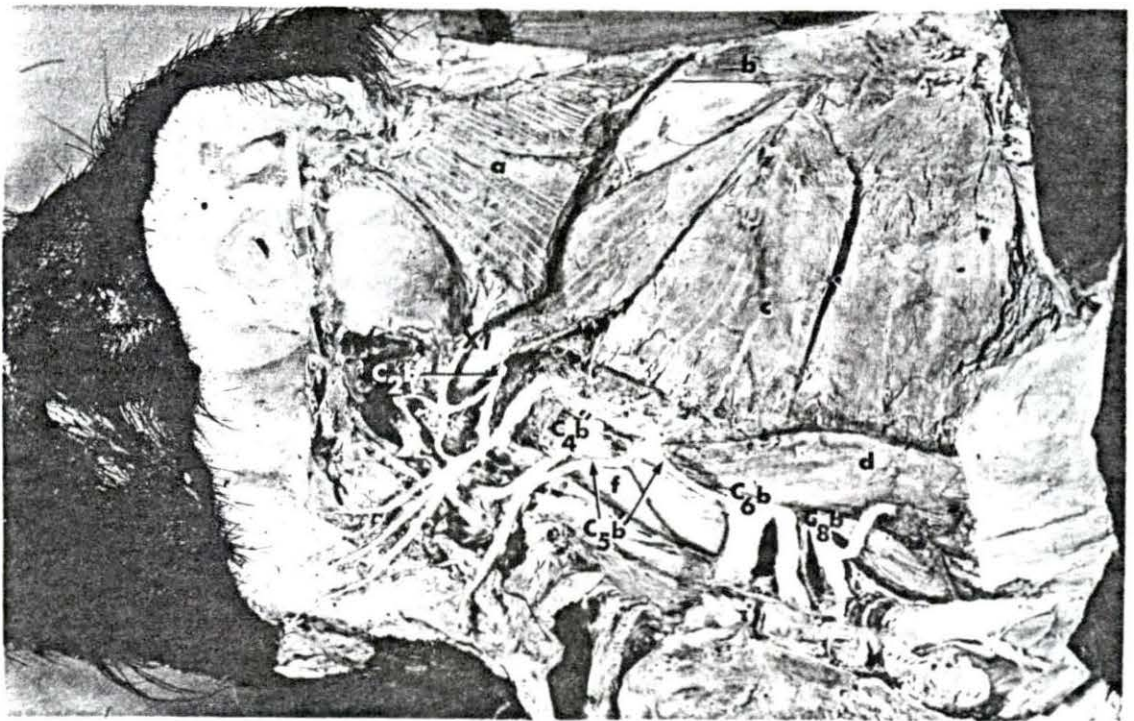
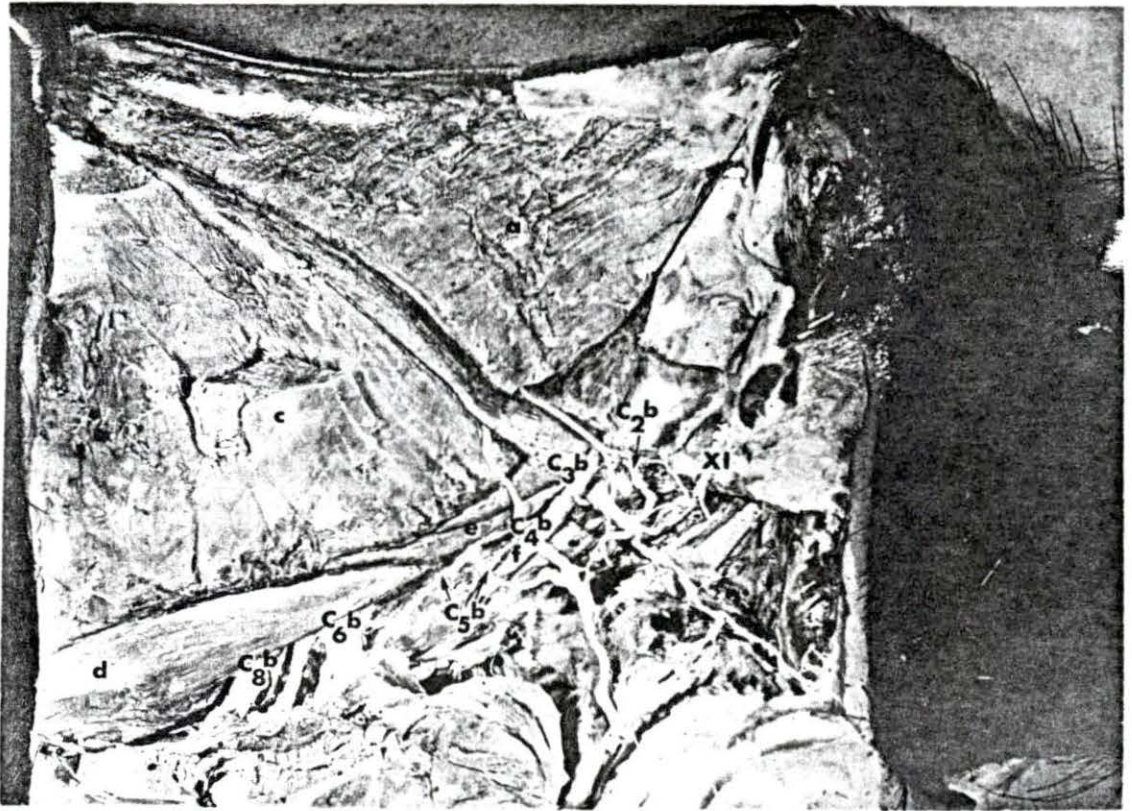


Plate No. 3. Left lateral view of the cervical region showing second type of arrangement of the ventral branches of cervical nerves

g	M. scalenus ventralis
n'	M. longissimus cervicis
i	M. longissimus capitis et atlantis
j	M. complexus
C ₁ b to C ₈ b	Rami ventrales Nn. spinales cervicales I to VIII
C ₃ b' to C ₅ b'	Medial branches of Rami ventrales Nn. spinales cervicales II to V
C ₃ b" to C ₅ b"	Lateral branches of Rami ventrales Nn. spinales cervicales II to V
R ₁	First rib

Plate No. 4. Right lateral view showing third type of arrangement of the ventral branches of cervical nerves

C ₂ b", C ₄ b", C ₆ b", C ₈ b"	q	M. intercostalis externus
		Lateral branches of Rami ventrales Nn. spinales cervicales II to VIII
		First to fifth rib
R ₁ to R ₅	T ₂ b" 5	Ramus perforantis N. intercostalis II

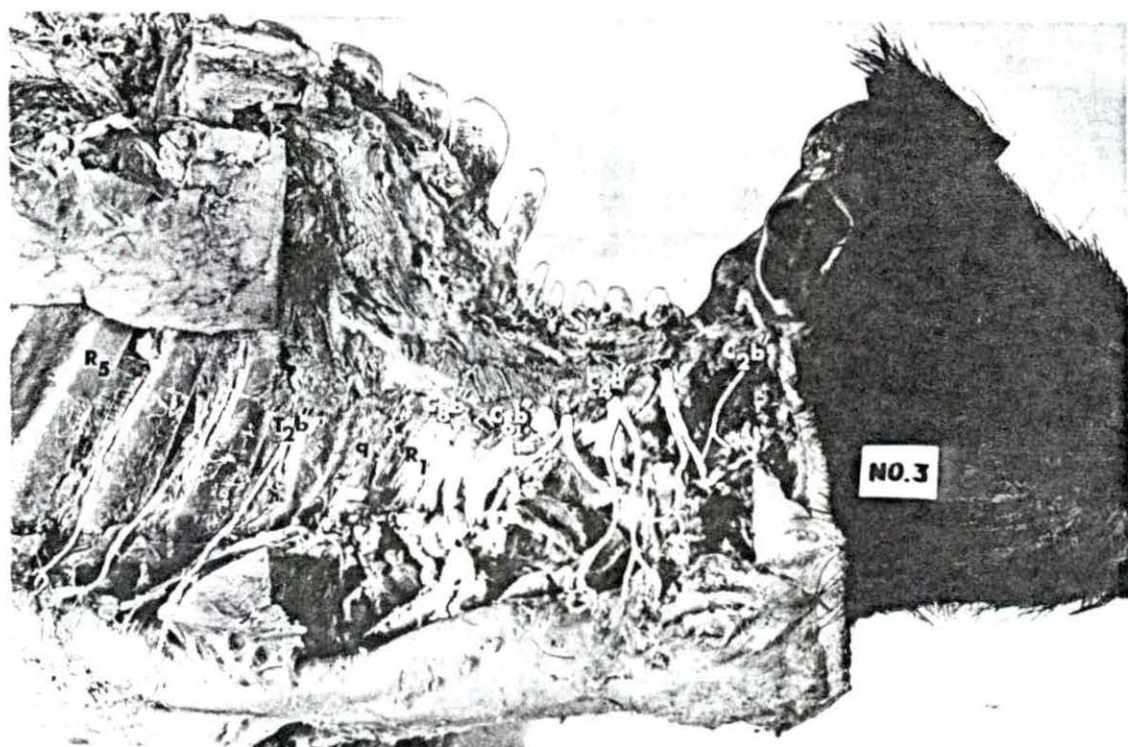
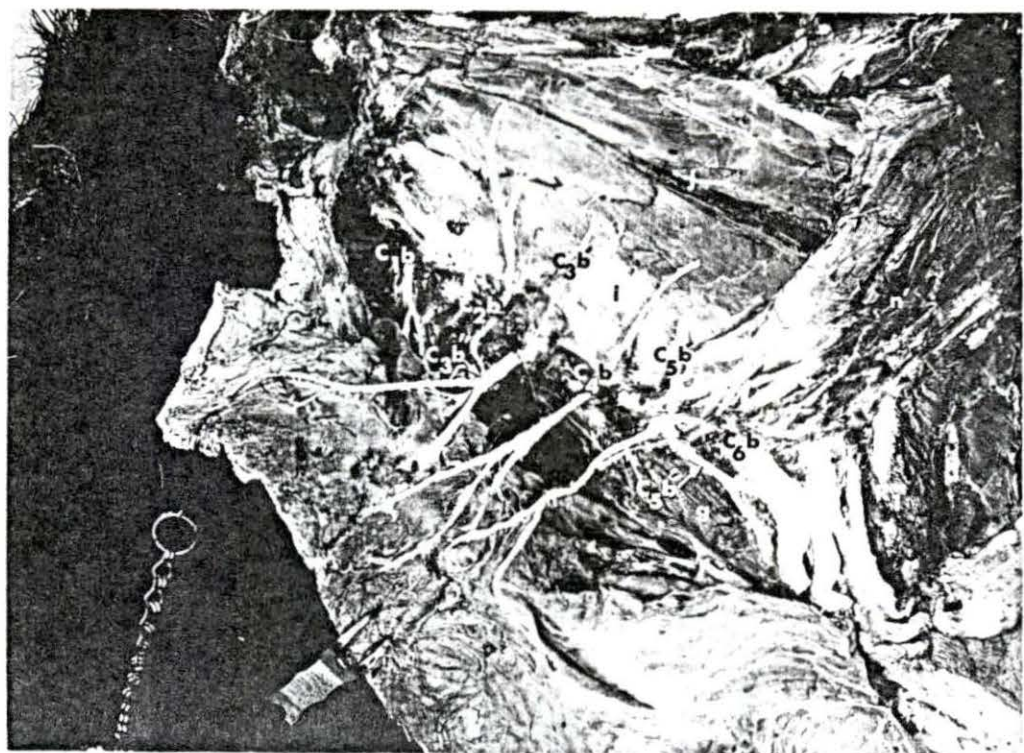


PLATE NO. 5 Superficial right lateral view of the thoracic and lumbar regions showing the various cutaneous branches of the thoracic and lumbar spinal nerves in relation with the superficial muscles

a'	M. trapezius pars thoracis
c'	M. serratus ventralis thoracis
k	M. latissimus dorsi
l	M. serratus dorsalis caudalis
m	M. obliquus abdominis externus
n	M. longissimus dorsi
L ₅ a'	Medial branch of the Ramus dorsalis N. spinalis lumbalis V
L ₅ a''	Lateral branch of the Ramus dorsalis N. spinalis lumbalis V
L ₂ b'	Cranial branch of the Ramus ventralis N. spinalis lumbalis II
Ta' - Ta'	Medial branches of the Rami dorsales Nn. spinales thoracici
Ta'' - Ta''	Lateral branches of the Rami dorsales Nn. spinales thoracici
T ₄ b'' - T ₁₅ b''	Rami perforantes of Nn. intercostales IV to XV
T ₉ b''' - T ₁₂ b'''	Lateral cutaneous branches of the Rami perforantes

Plate No. 6. Dorsal view of the thoracic and lumbar regions showing the course and distribution of the lateral branches of Rami dorsales Nn. spinales thoracici at lumbales

k M. lattivimus dorsi

L₆ Dorsal spinous process of the sixth lumbar vertebrae

L_{1a}" , L_{2a}" , L_{6a}" Lateral branches of Rami dorsales Nn. spinales lumbales I to VI

T₄ - T₁₆ Dorsal spinous processes of the thoracic vertebrae

T_{9a}" - T_{15a}" Lateral branches of the Rami dorsales Nn. spinales thoracici

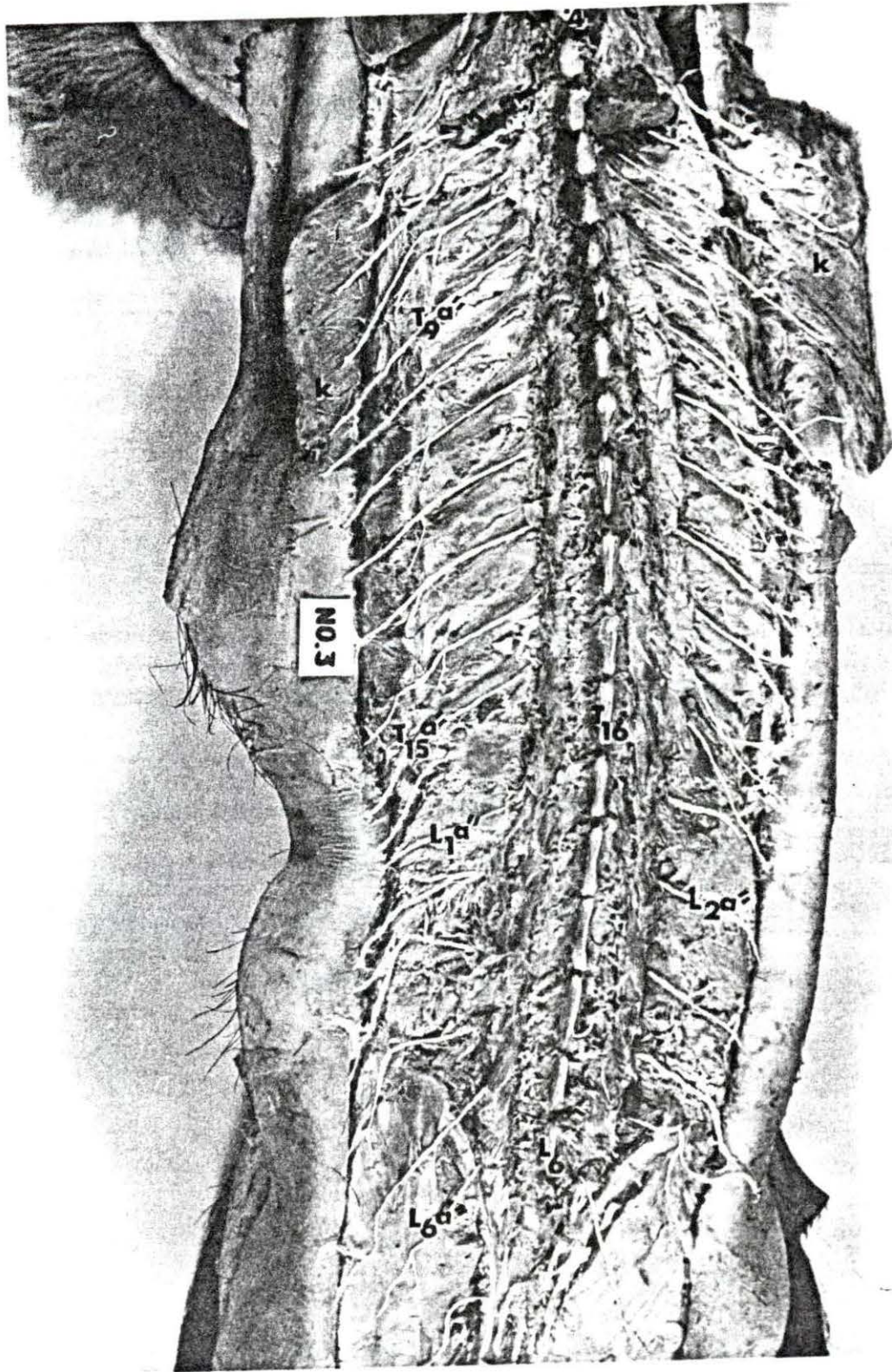


Plate No. 7. Left dorsolateral view showing the arrangement of branching course and disposition of the Rami dorsales Nn. spinales thoracici

a'	M. trapezius pars thoracic (right side)
o	M. multifidus dorsi
p	M. levatores coarctorum
q	M. intercostalis externus
T ₅ a', T ₁₀ a', T ₁₅ a'	Medial branches of Rami dorsales Nn. spinales thoracic V to XV
T ₅ a'', T ₁₅ a''	Lateral branches of Rami dorsales Nn. spinales thoracici V to XV

Plate No. 8. Left lateral view showing the emergence of Rami perforantes and the distribution of lateral cutaneous branches under the surface of the thoracic skin

q	Mm. intercostales externi
C ₈ b	Ramus ventralis N. cervicalis VIII
R ₁ , R ₉ , R ₁₅	First to last ribs
T ₁ b'', T ₇ b'', T ₁₄ b''	Rami perforantes Nn. intercostales I to XIV
T ₁ b''', T ₇ b''', T ₁₄ b'''	Lateral cutaneous branches of Rami perforantes
ll	N. thoracalis lateralis

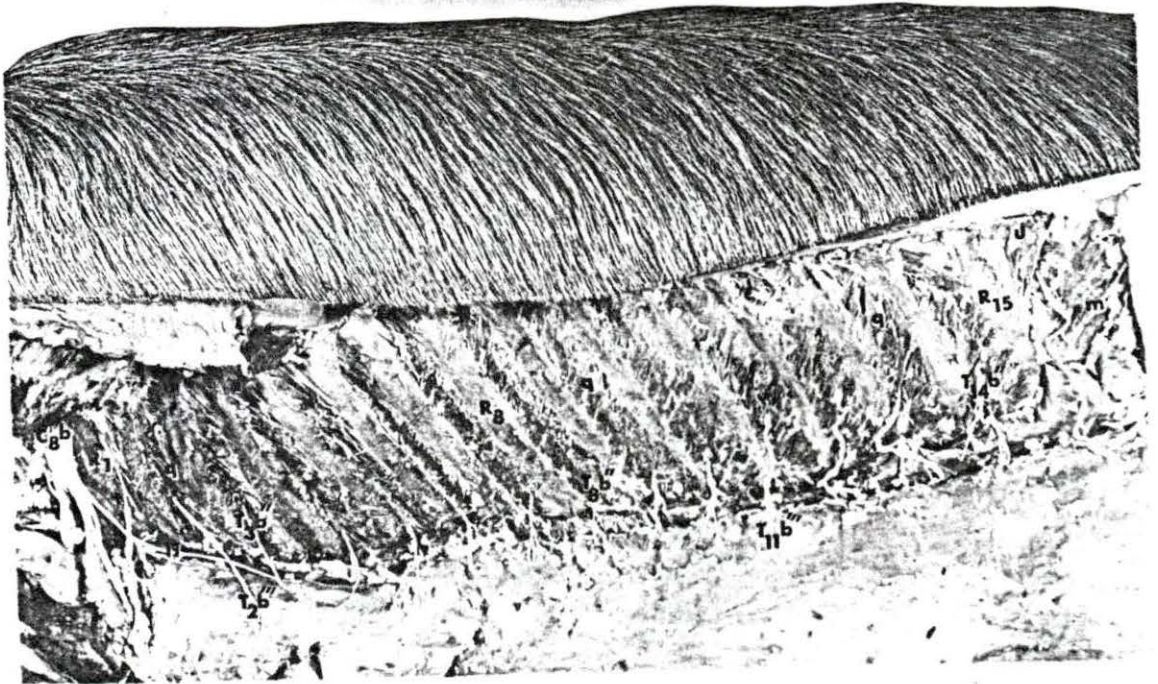
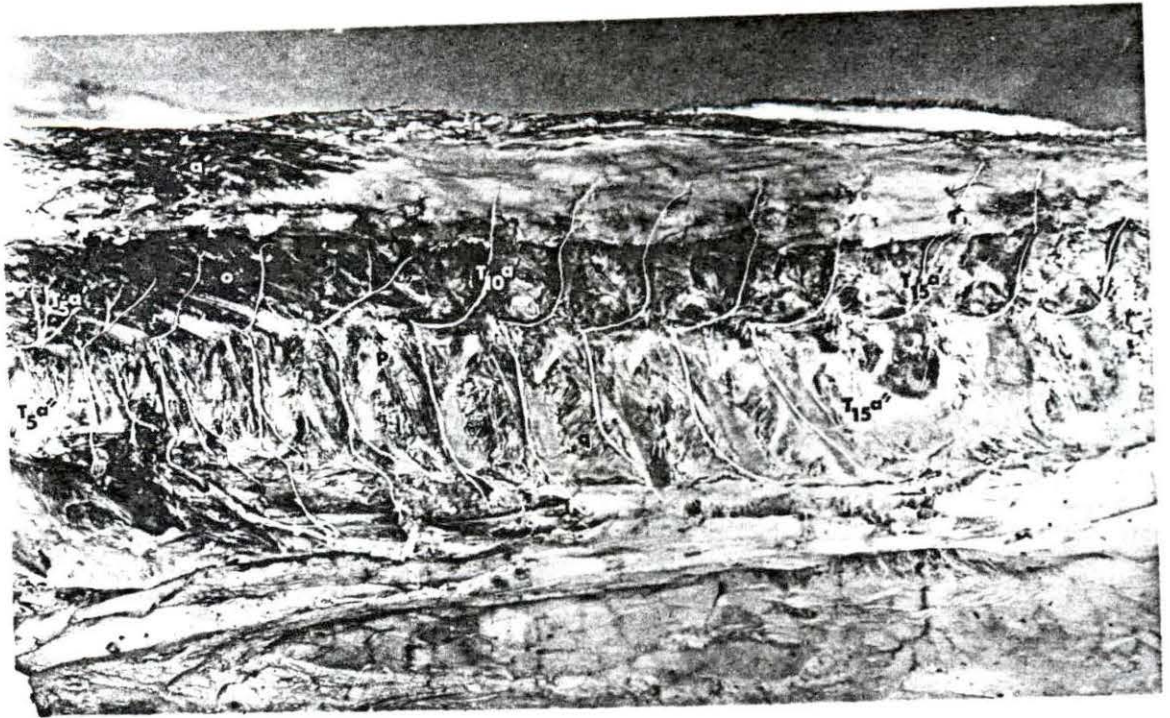


Plate No. 9. Left dorsolateral view of the thoracic and lumbar regions showing the course, branching and inter-relationship of the various cutaneous branches of the Rami dorsales and Rami ventrales of Nn. spinales thoracici et lumbales

C'	M. serratus ventralis thoracis
m	M. obliquus abdominis externus
q-q	Mm. intercostales externi
F	N. cutaneus femoris lateralis
G	Sub-iliac lymph node
L ₆	Dorsal spine of sixth lumbar vertebra
L _{1a} "	Lateral branch of Ramus dorsalis N. spinalis lumbalis I
L _{2b} '	Cranial branch of Ramus ventralis N. spinalis lumbalis II
R ₁₆	Sixteenth rib
T _{12b} "	Lateral cutaneous branch of the Ramus perforantis N. intercostalis XII
Tb""	Distal lateral cutaneous branches of Rami perforantes Nn. intercostales
ll	N. thoracalis lateralis

Plate No. 10. Left ventrolateral view of the thoracic and lumbar regions showing various cutaneous branches of the Rami ventrales Nn. spinales thoracici et lumbales

c'	M. serratus ventralis thoracis
m	M. obliquus abdominis externus
q-q	Mm. intercostales externi
y	Mm. praeputiales
F	N. cutaneus femoris lateralis
G	Sub-iliac lymph node
L _{1b} '	Cranial branch of the Ramus ventralis N. spinalis lumbalis I
R _{9-R₁₆}	Ninth and sixteenth ribs
Tb'	Ventral cutaneous branches
Tb""	Lateral cutaneous branches of the Rami perforantes of Nn. intercostales
Tb""	Distal lateral cutaneous branches of the Rami perforantes of Nn. intercostales

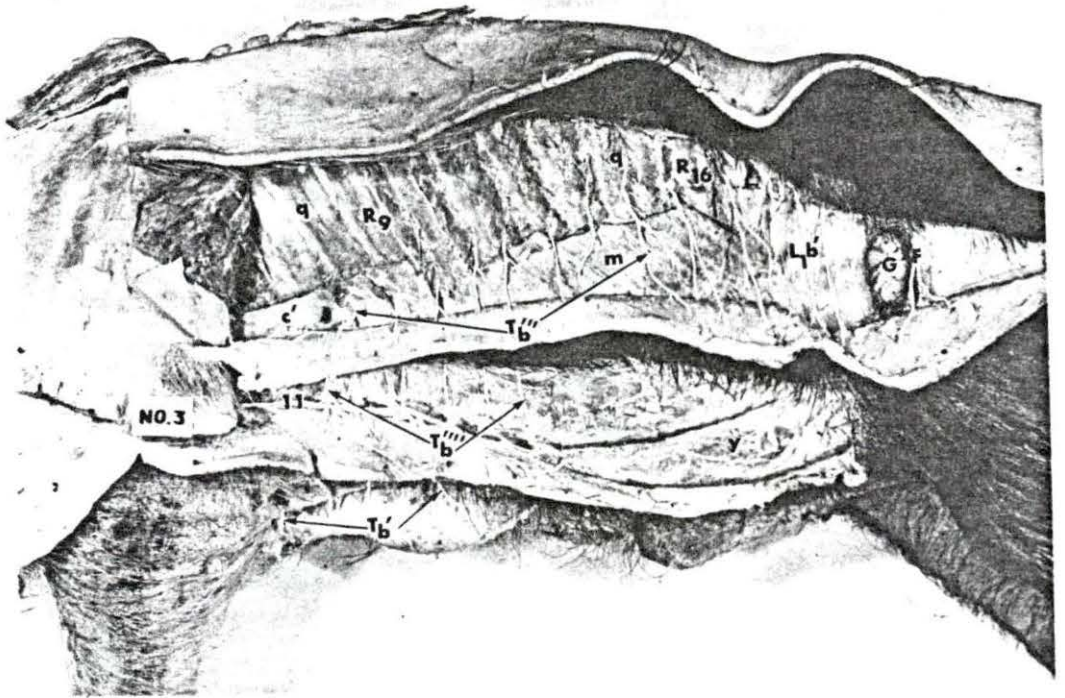
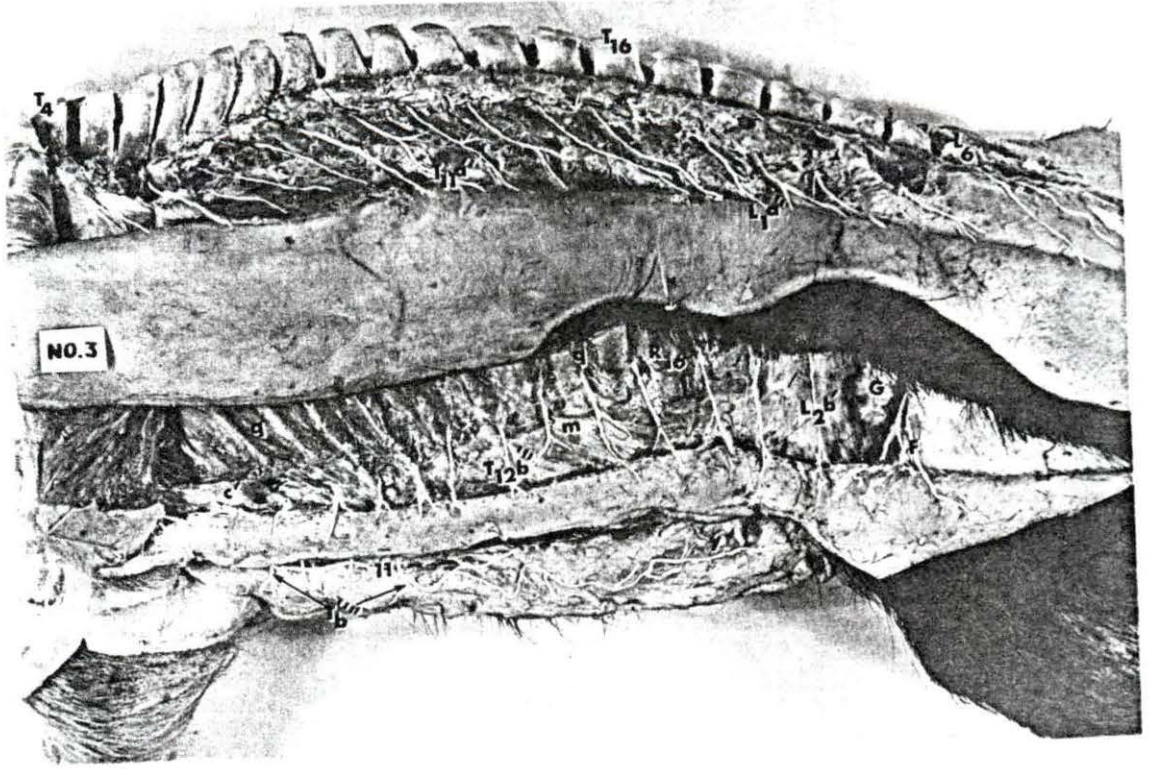


Plate No. 11. Left dorsolateral view showing the course, branching and disposition of Rami dorsales of Nn. spinales lumbales

o	M. multifidus dorsi
n	M. longissimus dorsi
L ₁ a', L ₅ a'	Medial branches of Rami dorsales Nn. spinales lumbales I to V
L ₁ a'', L ₅ a''	Lateral branches of Rami dorsales Nn. spinales lumbales I to V
M	Mammillary Process

Plate No. 12. Right lateral view showing the course, branching, and disposition of Rami ventrales of Nn. spinales lumbales et sacrales

m	M. obliquus abdominis externus
o	M. multifidus dorsi
t	M. gluteus profundus
x	M. vastus lateralis
L ₁ b - L ₃ b - L ₆ b	Rami ventrales Nn. spinales lumbales I to VI
L ₁ b'	Cranial branch of Ramus ventralis Nn. spinalis lumbalis I
L ₁ b''	Caudal branch of Ramus ventralis N. spinalis lumbalis I
L ₂ b'	Cranial branch of Ramus ventralis N. spinalis lumbalis II
L ₂ b''	Caudal branch of Ramus ventralis N. spinalis lumbalis II
F	N. cutaneus femoris lateralis
S ₁ b - S ₃ b	Rami ventrales Nn. spinales sacrales I to IV

Plate No. 13. Dorsal view showing the emergence of the Rami dorsales Nn. spinales coccygei and formation of the truncus coccygeus dorsalis


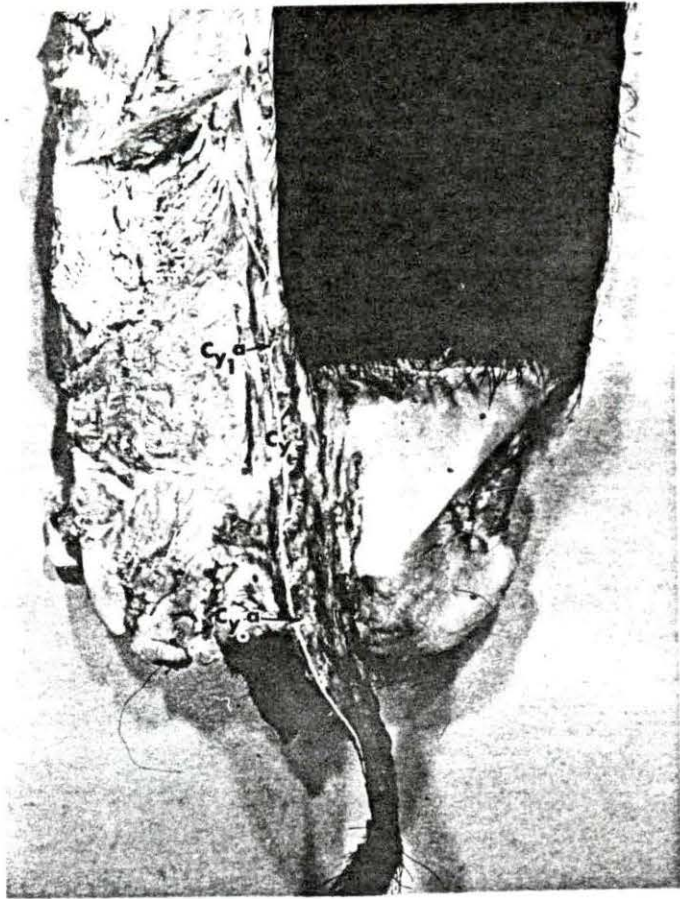
Cy' Truncus coccygeus dorsalis

Cy_{1a}' - Cy_{6a}' Rami dorsales Nn. spinales coccygei I to VI

Plate No. 14. Ventral view showing the emergence of Rami ventrales Nn. spinales coccygei and formation of truncus coccygeus ventralis

Cy" Truncus coccygeus ventralis

Cy_{1b} - Cy_{6b} Rami ventrales Nn. spinales coccygei I to VI



169a

X. APPENDIX B

FIG. NO. 1 A lateral view showing the emergence, branching and distribution of the cutaneous branches of the cervical nerves in relation with the superficial muscles of the cervical region.

a	M. trapezius cervicis
a'	M. trapezius thoracis
b	M. brachiocephalicus
d	M. sternocephalicus
e	M. omotransversarius
f	M. omohyoideus
g	M. sternothyroideus
C ₂ a' - C ₇ a'	Rami mediales of R. dorsales Nn. spinales cervicales II to VII
C ₂ + 3b''	Rami laterales of R. ventrales Nn. spinales cervicales II et III

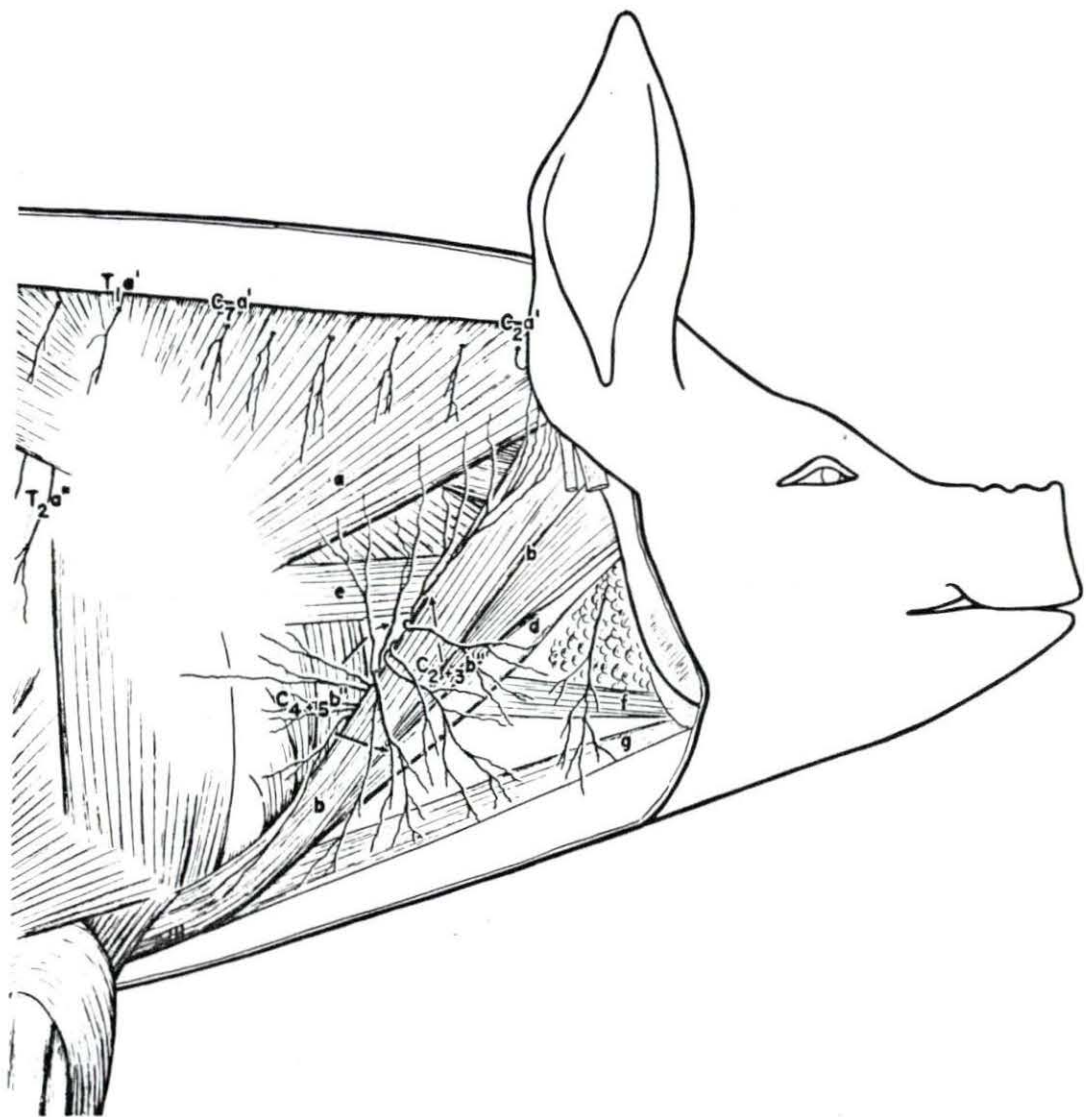


FIG. NO. 2 A lateral view of the cervical and thoracic regions showing the emergence and branching of the Rami ventrales of Nn. spinales cervicales et thoracici in relation with the deeper muscles of these regions.

a	N. trapezius pars thoracis
a'	N. trapezius pars cervicis
b	M. brachiocephalicus
d	M. sternocephalicus
h	M. latissimus dorsi
i	M. obliquus abdominis externus
j	M. serratus dorsalis caudalis
m	M. pectoralis caudalis profundus
x	Mm. intertransversarii dorsalis cervicis
x'	Mm. intertransversarii ventralis cervicis
v	M. serratus ventralis thoracis
v'	M. serratus ventralis cervicis
w	M. scalenus dorsalis
w'	N. scalenus ventralis
S	Scapula
V	Jugular Vein
A	N. auricularis magnus
C ₁ b	Ramus ventralis N. spinalis cervicalis I
C ₂ a' to T ₁₂ a'	Rami mediales of R. dorsales Nn. spinales cervicales et thoracici
C ₂₊₃ b"	Rami laterales of R. ventrales Nn. spinales cervicales II and III
C ₄ b"	Rami lateralis of R. ventralis N. spinalis cervicalis IV
C ₄₊₅ b"	Rami laterales of R. ventrales N. spinales cervicales IV and V
T ₂ a" - T ₁₂ a"	Rami laterales of R. dorsales Nn. spinales thoracici II to XII
T ₂ b'	Rami cutanei ventrales Nn. intercostales
T ₂ b"	Ramus perforantis N. intercostalis II
T ₁₀ b"'	Ramus cutaneus lateralis of R. perforantis X
T ₁₀ b""	Ramus cutaneus lateralis distalis of R. perforantis X
ll	N. thoracalis lateralis

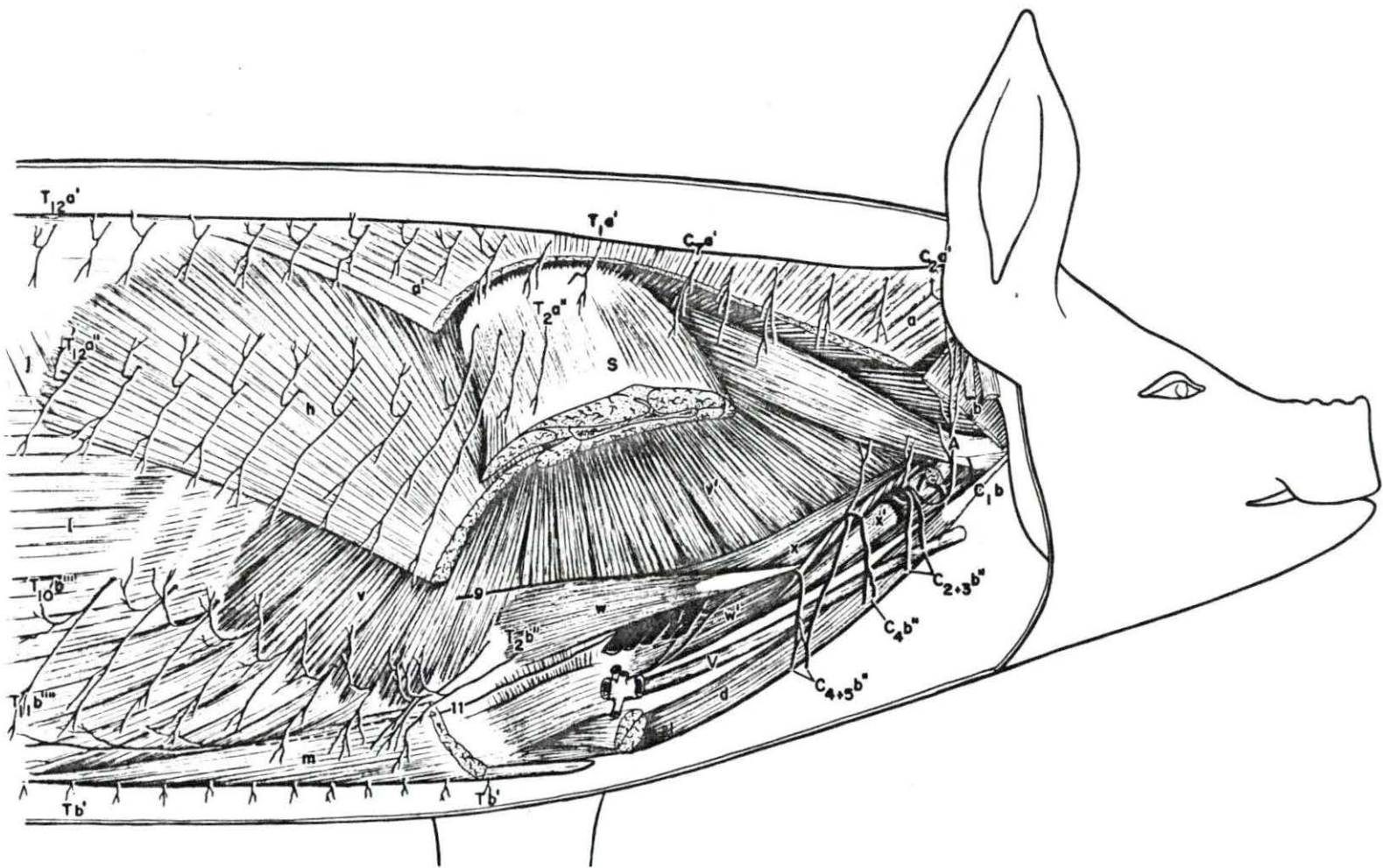


FIG. NO. 3 A right lateral view of the cervical region showing the course, branching and intercommunicating branches of medial and lateral branches of Rami ventrales.

b	M. brachiocephalicus
d	M. sternocephalicus
r'	M. longissimus cervicis
t	M. iliocostalis
x'	Mm. intertransversarii ventrales cervicis
w	M. scalenus dorsalis
y - y'	M. rhomboideus
z - z'	M. complexus
V	Jugular Vein
A	N. auricularis magnus
C _{2a} ' - C _{7a} '	Rami mediales of R. dorsales Nn. spinales cervicales I to VII
C _{1b}	Ramus ventralis N. spinalis cervicalis I
C _{4b} '	Ramus medialis of R. ventralis N. spinalis cervicalis IV
C _{2+3b} "	Rami laterales of R. ventrales Nn. spinales cervicales II and III
C _{4b} "	Ramus lateralis of R. ventralis N. spinalis cervicalis IV
C _{4+5b} "	Rami laterales of R. ventrales Nn. spinales cervicales IV and V

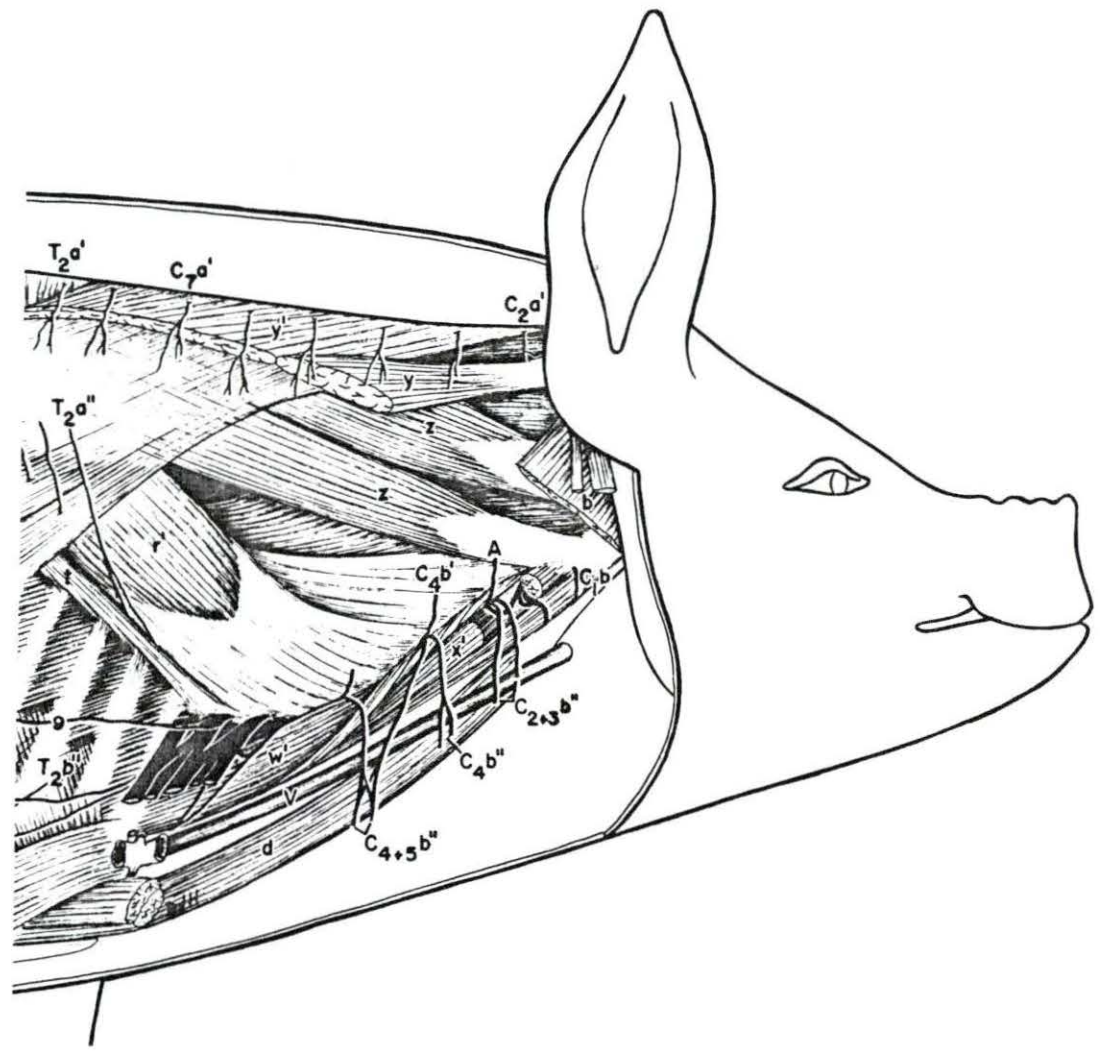


FIG. NO. 4 A deeper view of the cervical region showing the course followed and formation of the dorsal cervical plexus and ventral cervical plexus by the Rami dorsales and ventrales.

b	M. brachiocephalicus
d	M. sternocephalicus
x'	M. intertransversarii ventralis cervicis
w'	M. scalenus ventralis
A	N. auricular magnus
V	Jugular Vein
C _{2a'} - C _{7a'}	Rami mediales of R. dorsales Nn. spinales cervicales II to VII
C _{1b} to C _{8b}	Rami ventrales of Nn. spinales cervicales I to VIII
C _{4b'}	Ramus medialis of R. ventralis N. spinalis cervicalis IV
C _{2+3b''}	Rami laterales of R. ventrales II and III
C _{4b''}	Ramus lateralis of R. ventralis IV
C ₄ + C _{5b''}	Rami laterales of Rami ventrales IV and V

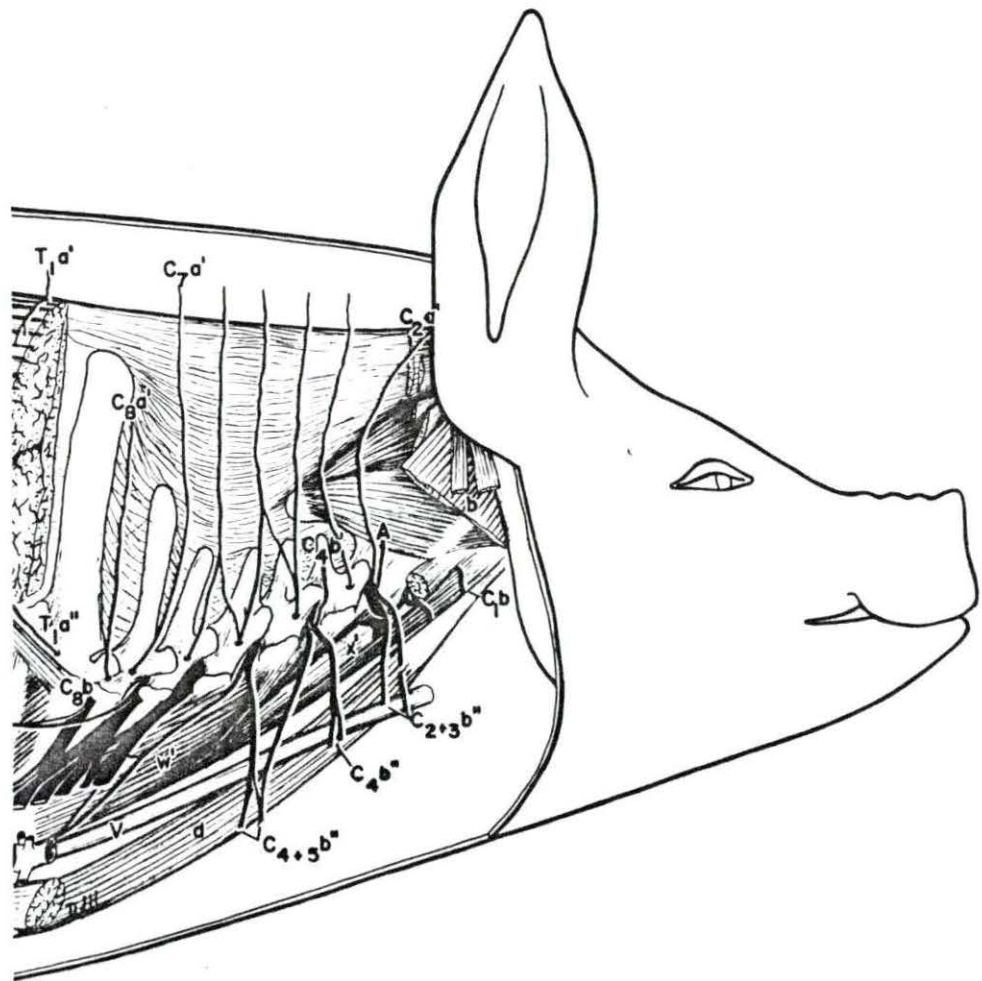


FIG. NO. 5 A schematic right lateral view showing the emergence of the Rami dorsales and Rami ventrales through their respective foramina and their relationship with the vertebrae.

A	N. auricularis magnus
C ₁ a' - C ₇ a'	Rami mediales of Rami dorsales Nn. spinales cervicales I to VII
C ₁ b - C ₈ b	Rami ventrales of Nn. spinales cervicales I to VIII
C ₄ b'	Ramus medialis of Ramus ventralis N. spinalis cervicalis IV
C ₃ b" - C ₅ b"	Rami lateralis of Rami ventrales N. spinales cervicales
G	Foramen vertebralis lateralis

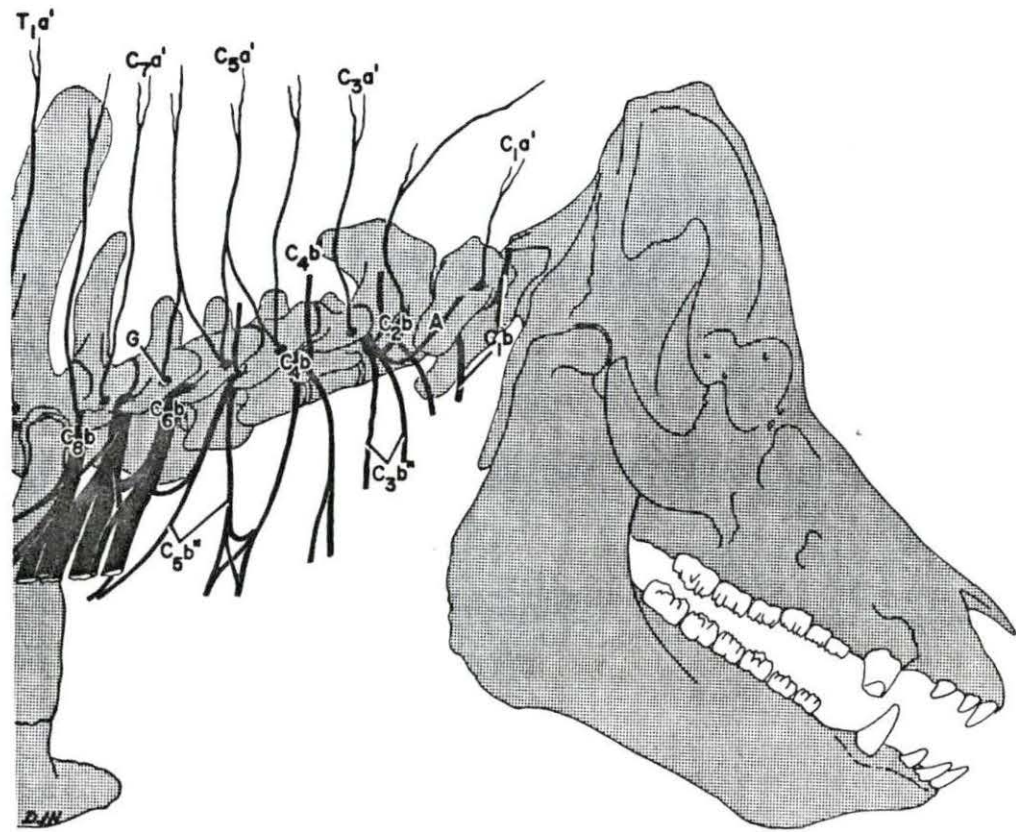


FIG. NO. 6 Right lateral view of the thoracic region showing various cutaneous branches in relation with the superficial muscles.

a'	M. trapezius pars thoracis
h	M. latissimus dorsi
i	M. obliquus abdominis externus
j	M. serratus dorsalis caudalis
m	M. caudalis pectoralis profundus
r	M. longissimus dorsi
T ₁ a' - T ₁₅ a'	Rami mediales of R. dorsales Nn. spinales thoracici I to XV
T ₂ a" - T ₁₅ a"	R. laterales of R. dorsales Nn. spinales thoracici II to XV
Tb' - Tb'	Rami cutanei ventrales
T ₅ b" - T ₁₄ b"	Rami perforantes Nn. intercostales
T ₇ b"" - T ₁₁ b""	Rami cutanei laterales of R. perforantes
T ₃ b"" - T ₁₂ b""	Rami cutanei laterales distales of R. perforantes
ll	M. thoracalis lateralis

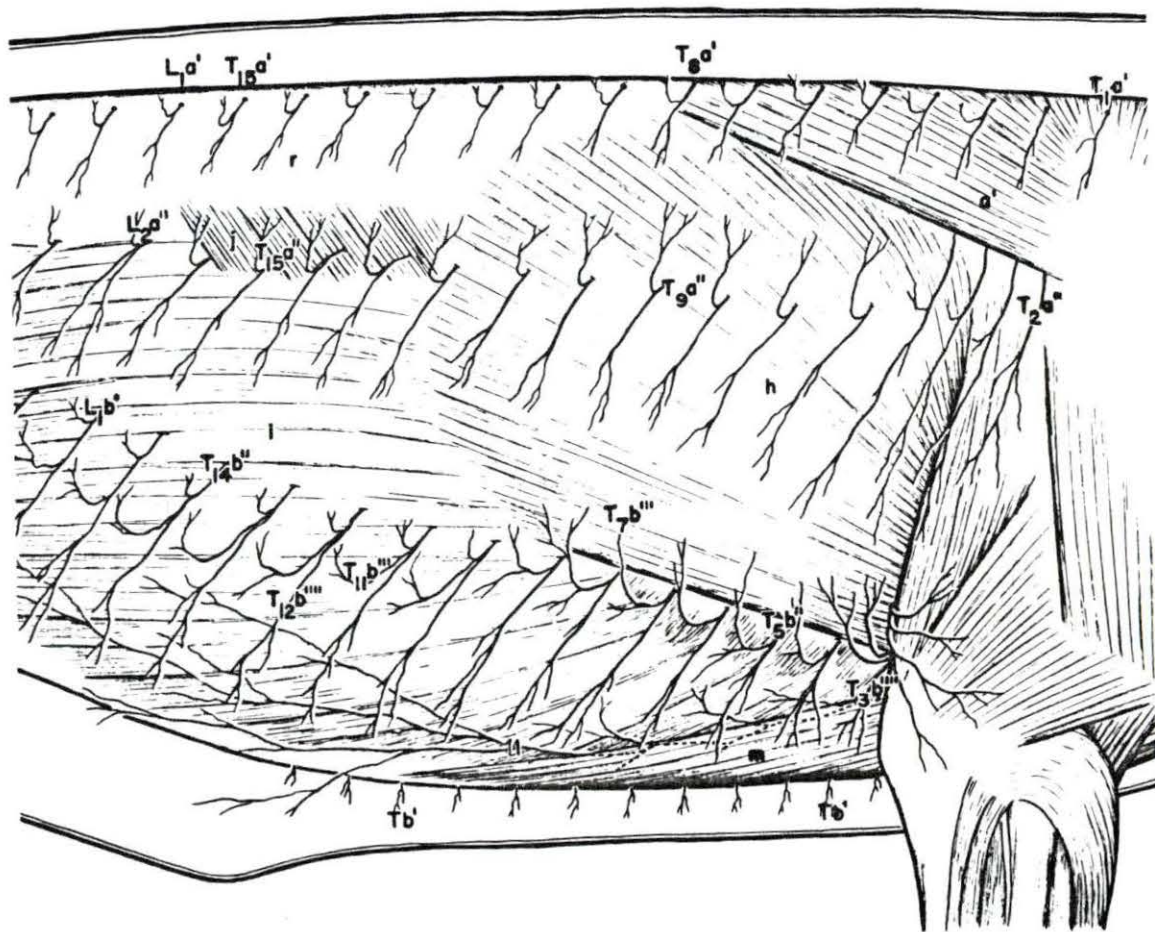


FIG. NO. 7 A dorsolateral view of the thoracic and lumbar regions showing the emergence and division of the Rami dorsales into Rami mediales and Rami lateralis and the course followed by these branches in relation with the muscles of the dorsal aspect.

c	Mm. multifidus dorsi
c'	Mm. levatores costarum
j''	M. retractor costae
k	M. obliquus abdominis intermus
r	N. longissimus dorsi
s	Mm. intercostales externi
s'	Mm. intercostales interni
t	M. iliocostalis
M	Mammillary process
L _{1a} ' - L _{6a} '	Rami mediales of Rami dorsales Nn. spinales lumbales I to VI
L _{1a} '' - L _{6a} ''	Rami laterales of Rami dorsales Nn. spinales lumbales I to VI
T _{8a} ' - T _{15a} '	Rami mediales of Rami dorsales Nn. spinales thoracici VIII to XV
T _{8a} '' - T _{15a} ''	Rami laterales of Rami dorsales Nn. spinales thoracici VIII to XV

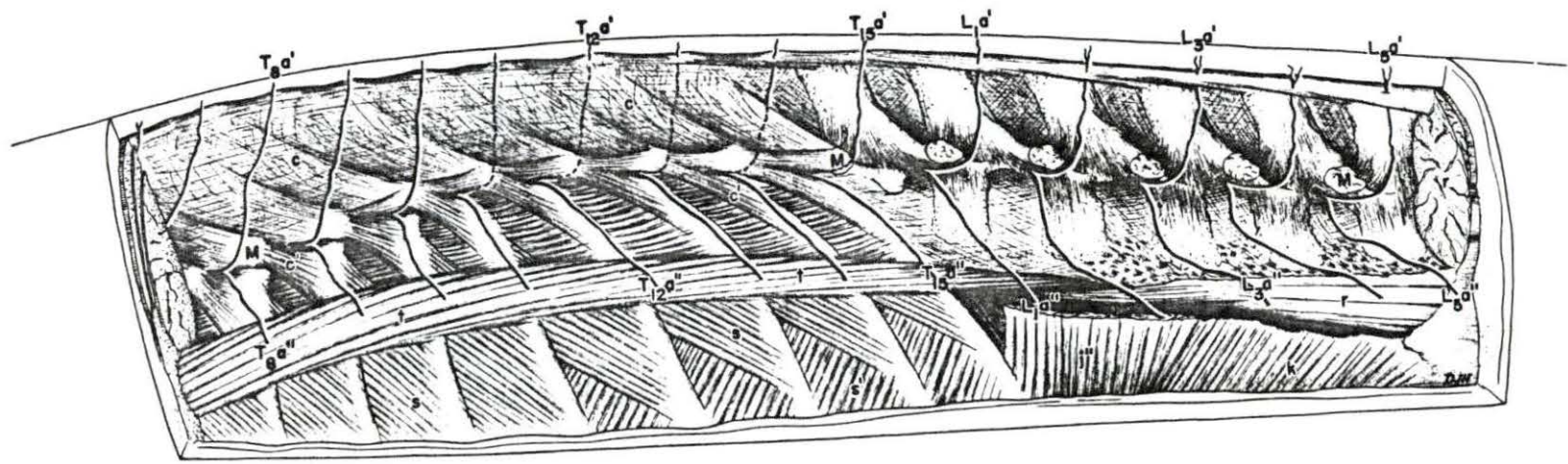


FIG. NO. 8 A right lateral view of the thoracic and lumbar regions showing the emergence of Rami perforantes of Nn. intercostales and Rami dorsales and their subdivision into Rami cutanei laterales and Rami cutanei laterales distales - their course and ramification.

i	M. obliquus abdominis externus
j	M. serratus dorsalis caudalis
j'	M. serratus dorsalis cranialis
j''	M. retractor costae
k	M. obliquus abdominis internus
l	M. transversus abdominis
m	M. pectoralis caudalis profundus
r	M. longissimus dorsi
s	Mm. intercostales externi
s'	Mm. intercostales interni
t	M. iliocostalis
v	M. serratus ventralis thoracis
T ₂ a' - L ₁ a'	Rami mediales of R. dorsales Nn. spinales thoracici et lumbales
T ₂ a'' - L ₆ a''	Rami laterales of R. dorsales Nn. spinales thoracici et lumbales
T ₂ b'' - T ₁₅ b''	Rami perforantes of Nn. intercostales
L ₂ b'	Cranial branch of R. ventralis N. spinalis lumbalis II
T ₁₂ b'''	Ramus cutaneus lateralis of R. perforantis XII
T ₁₂ b''''	Ramus cutaneus lateralis distalis of R. perforantis XII
9	N. thoracalis longus
11	N. thoracalis lateralis

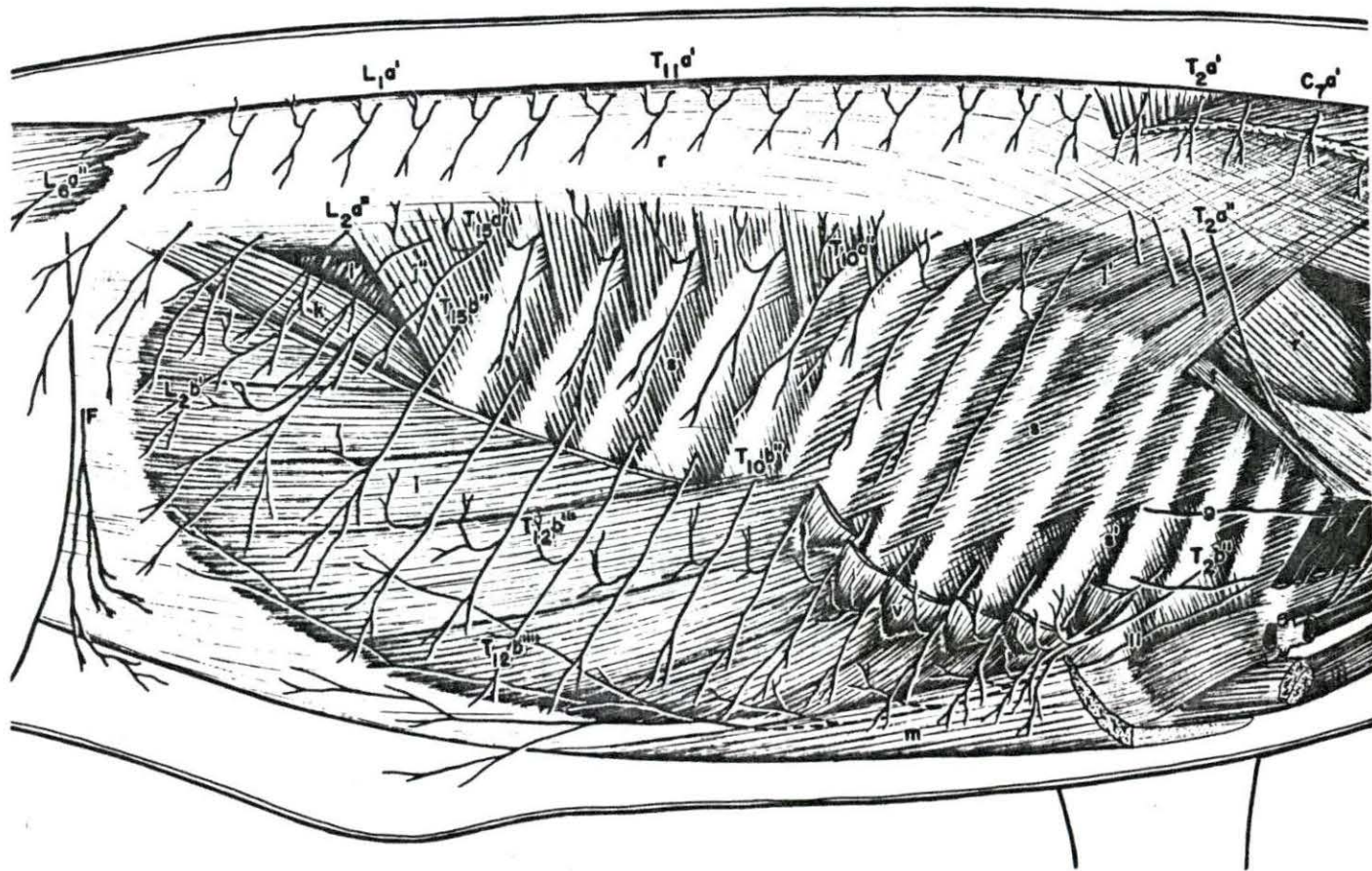


FIG. NO. 9 A view of the deep dissection of the thoracic and lumbar regions showing the relationship of the branches terminating as cutaneous branches with the deep muscles of the thoracic and lumbar regions.

i	M. obliquus abdominis externus
j"	M. retractor costae
k	M. obliquus abdominis internus
l	M. transversus abdominis
m	M. pectoralis caudalis profundus
r	M. longissimus dorsi
r'	M. longissimus cervicis
s	Mm. intercostales externi
s'	Mm. intercostales interni
t	M. iliocostalis
T ₁ a' - L ₅ a'	Rami mediales of R. dorsales Nn. spinales thoracici et lumbales
T ₁ a" - L ₆ a"	Rami laterales of R. dorsales Nn. spinales thoracici et lumbales
L ₂ b'	Cranial branch of R. ventralis N. spinales lumbalis II
T ₂ b" - T ₁₅ b"	Rami perforantes of Nn. intercostales
Tb'	Rami cutanei ventrales
F	N. cutaneus femoris lateralis
g	N. thoracalis longus
ll	N. thoracalis lateralis

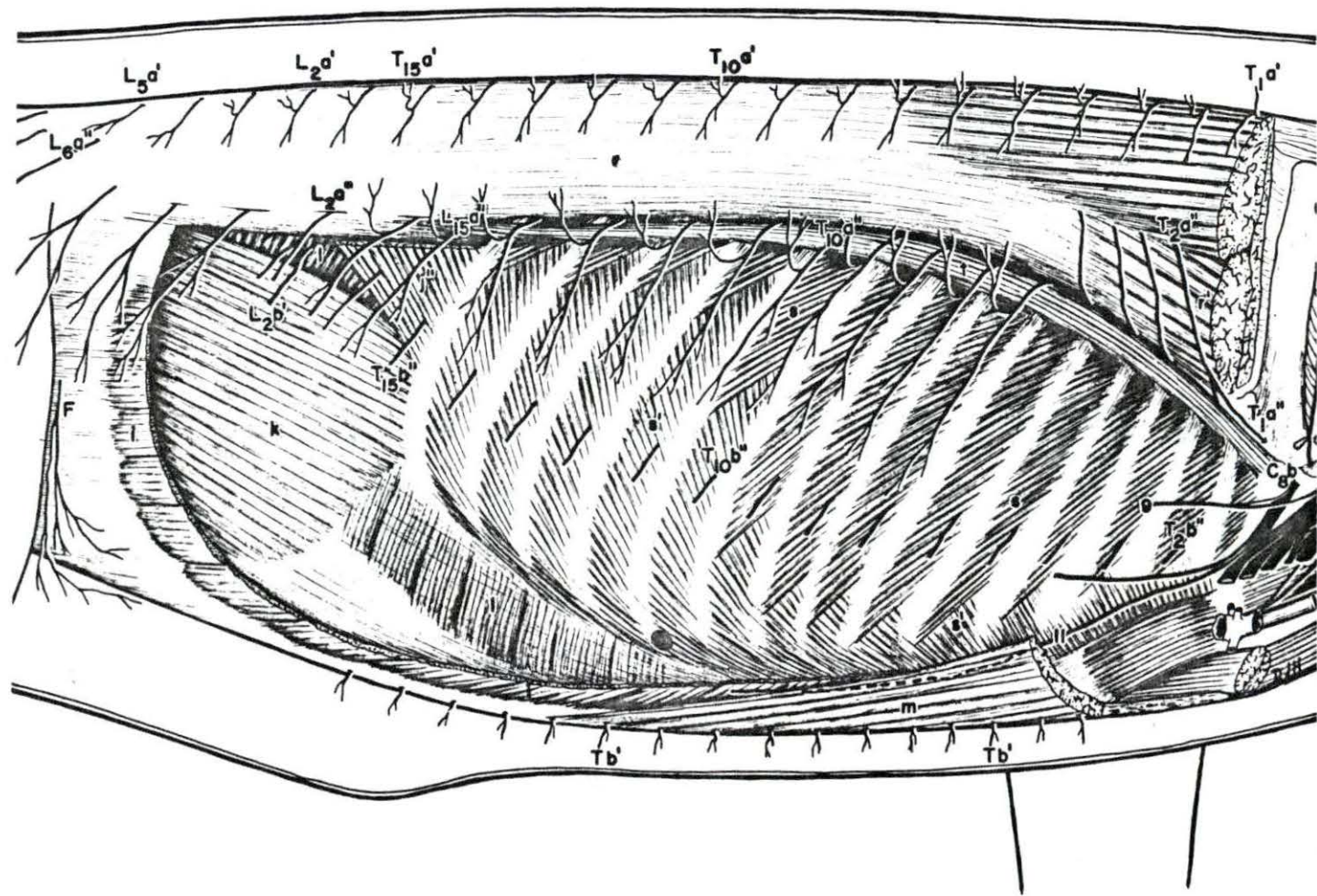


FIG. NO. 10 A ventrolateral view of the thoracic and lumbar regions showing the innervation of the mammary glands by way of Rami cutanei ventrales.

a'	M. trapezius pars thoracis
i	M. obliquus abdominis externus
j	M. serratus dorsalis caudalis
m	M. pectoralis caudalis profundus
r	M. longissimus dorsi
v	M. serratus ventralis thoracis
L ₁ a" - L ₄ a"	Rami laterales of R. dorsales Nn. spinales lumbales I to IV
L ₁ b'	Cranial branch of Ramus ventralis N. spinalis lumbalis I
L ₂ b"	Caudal branch of Ramus ventralis N. spinalis lumbalis II
T ₅ b' - T ₁₅ b'	Rami cutanei ventrales of Nn. intercostales
T ₄ b"" - T ₁₃ b""	Rami cutanei laterales of R. perforantes
T ₄ b"" - T ₁₃ b""	Rami cutanei laterales distales of R. perforantes
F	N. cutaneus femoris lateralis
ll	N. thoracalis lateralis

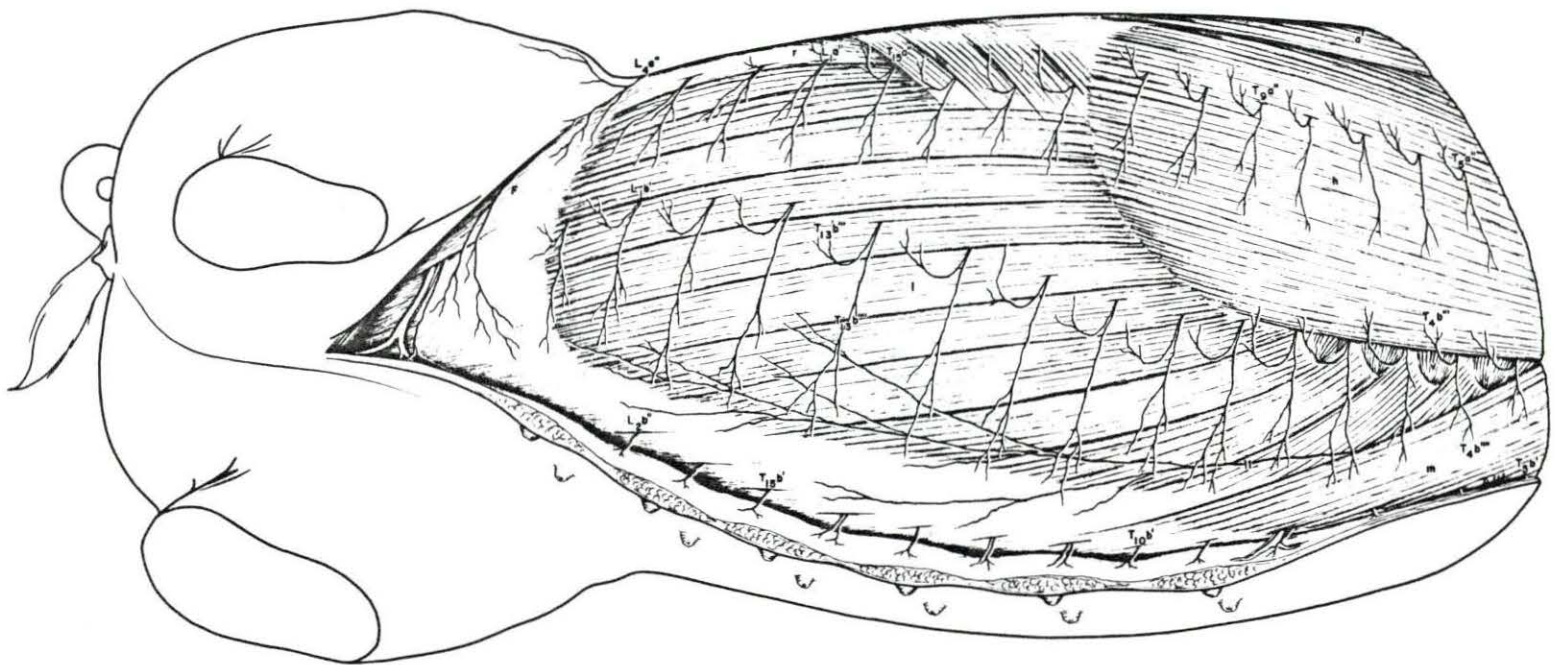


FIG. NO. 11 A cross section at the level of sixth rib showing the emergence and division of a typical thoracic spinal nerve into Ramus dorsalis and ventralis; their further subdivisions and relationship with the overlying muscles to finally terminate as cutaneous branches.

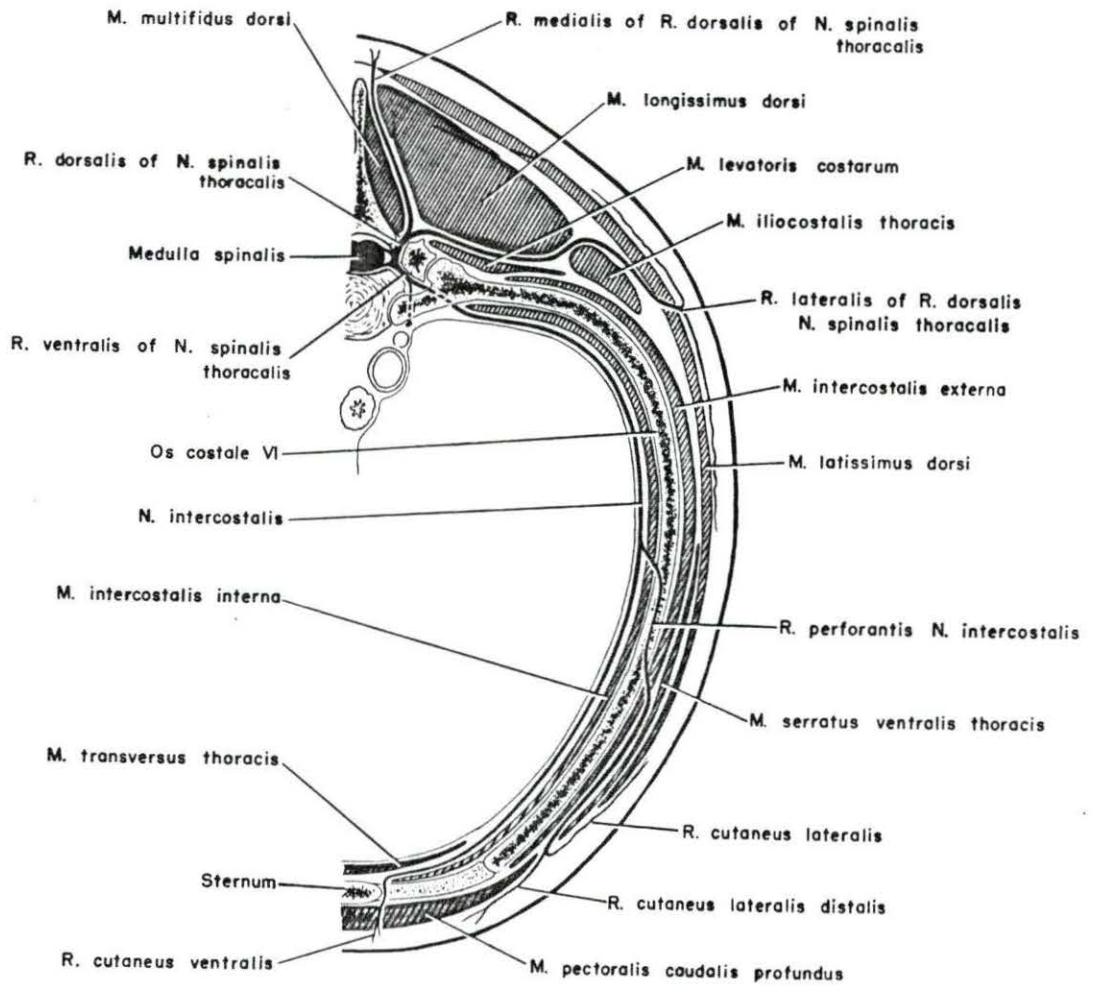


FIG. NO. 12 A schematic view showing the emergence of Rami dorsales and ventrales of Nn. spinales thoracici through foramina vertebralis lateralis dorsalis and ventralis and their relation with the vertebrae.

R	Foramina vertebralis lateralis dorsalis et ventralis
T _{1a} ' - T _{15a} '	Rami mediales of Rami dorsales Nn. spinales thoracici I to XV
T _{2a} " - T _{14a} "	Rami laterales of Rami dorsales Nn. spinales thoracici I to XV
T _{2b} - T _{15b}	Rami ventrales Nn. spinales thoracici II to XV
T _{2b} ' - T _{15b} '	Rami cutanei ventrales of Nn. intercostales
T _{4b} " - T _{12b} "	Rami perforantes Nn. intercostales
ll	N. thoracalis lateralis

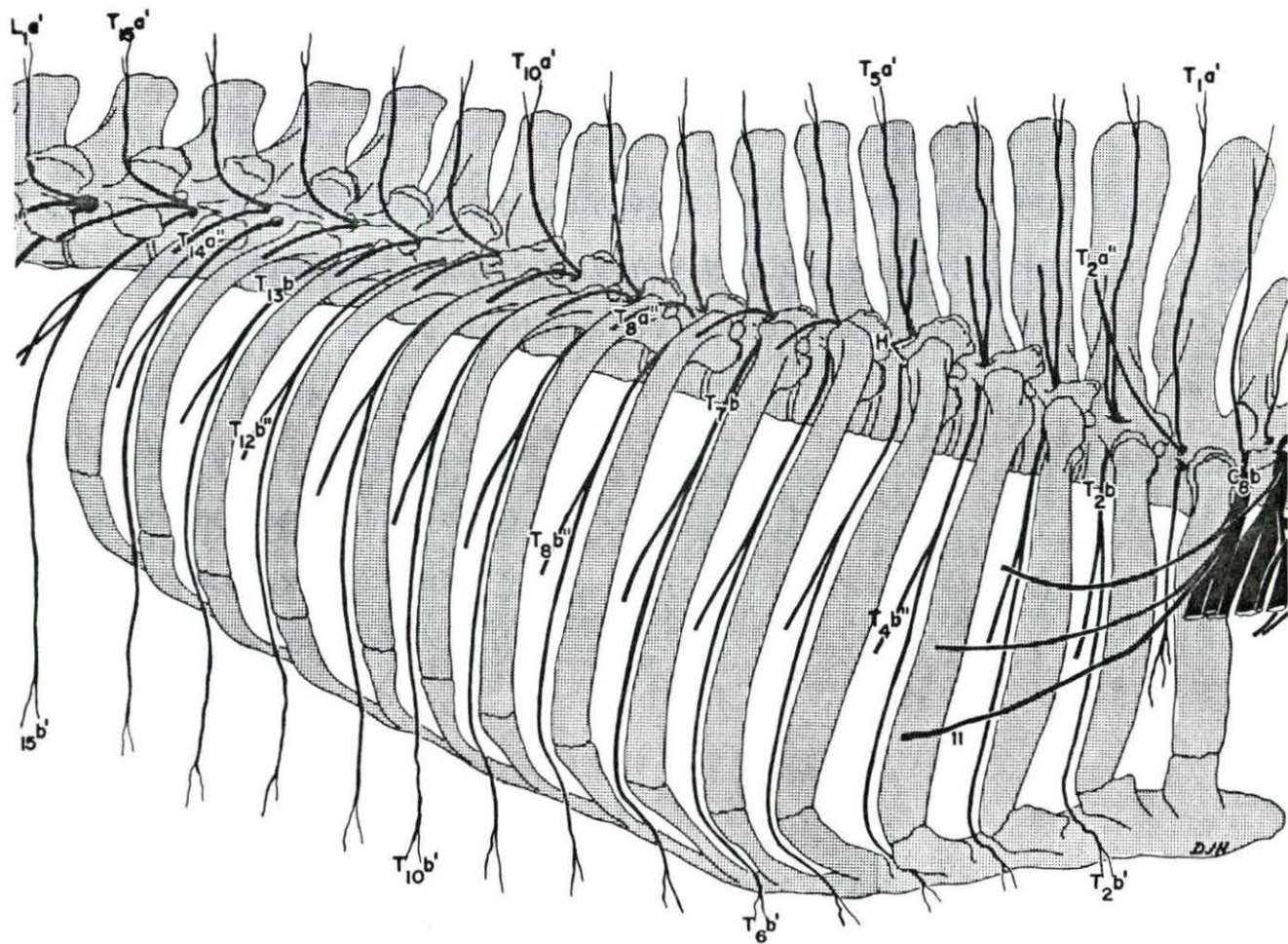


FIG. NO. 13 A right dorsolateral view of the lumbar and sacral regions showing the various branches in relation with the superficial muscles.

i	M. obliquus abdominis externus
j	M. serratus dorsalis caudalis
n	M. tensor fascia latae
o	M. biceps femoris
o'	M. gluteobiceps
p	M. semitendinosus
q	M. semimembranosus
r	M. longissimus dorsi
u	M. gluteus medius
L ₁ a' - L ₆ a'	Rami mediales of R. dorsales Nn. spinales lumbales I to VI
L ₂ a" - L ₆ a"	Rami laterales of R. dorsales Nn. spinales lumbales I to VI
L ₁ b'	Cranial branch of R. ventralis N. spinalis lumbalis I
S ₁ a" - S ₃ a"	Rami laterales of R. dorsales Nn. spinales sacrales I to III
D	N. cutaneus femoris caudalis
F	N. cutaneus femoris lateralis

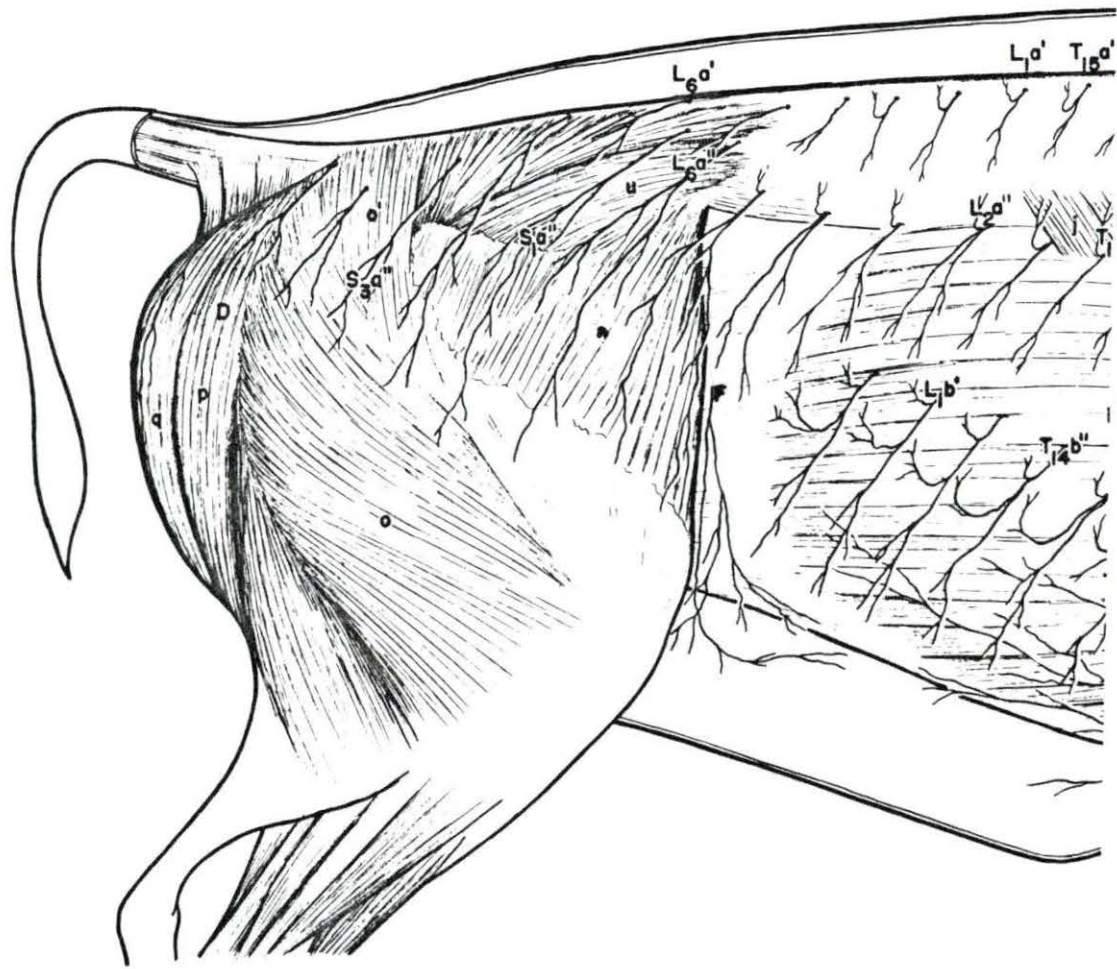


FIG. NO. 14 A schematic drawing of the lumbar and sacral nerves as these emerge through the intervertebral foramina showing their interrelationship and branching.

F	N. cutaneus femoris lateralis
L ₁ a' - L ₆ a'	Rami mediales of Rami dorsales Nn. spinales lumbales I to VI
L ₂ a" - L ₆ a"	Rami laterales of Rami dorsales Nn. spinales lumbales
L ₄ b	Ramus ventralis N. spinalis lumbalis IV
L ₁ b'	Cranial branch of Ramus ventralis N. spinalis lumbalis I
L ₂ b'	Cranial branch of Ramus ventralis N. spinalis lumbalis II
L ₁ b"	Caudal branch of Ramus ventralis N. spinalis lumbalis I
L ₂ b"	Caudal branch of Ramus ventralis N. spinalis lumbalis II
S ₁ a - S ₄ a	Rami dorsales Nn. spinales sacrales I to IV
S ₁ b - S ₃ b	Rami ventrales Nn. spinales sacrales I to IV

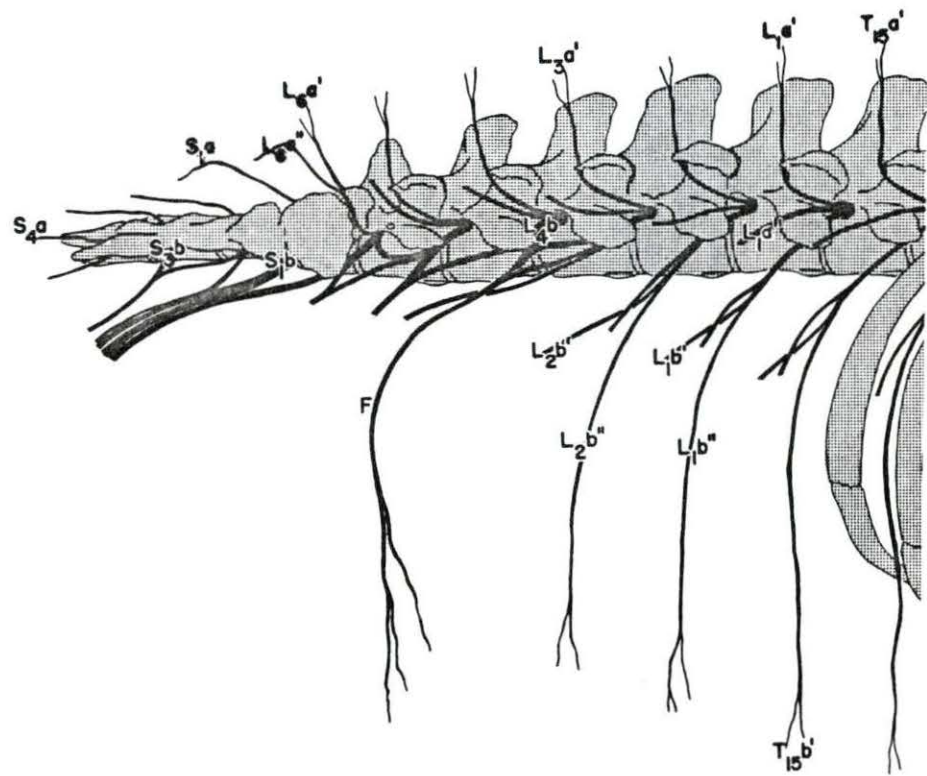


FIG. NO. 15a A schematic dorsal view of the sacral and coccygeal region showing the emergence of the Rami dorsales of Nn. spinales coccygei and the formation of the truncus coccygeus dorsalis.

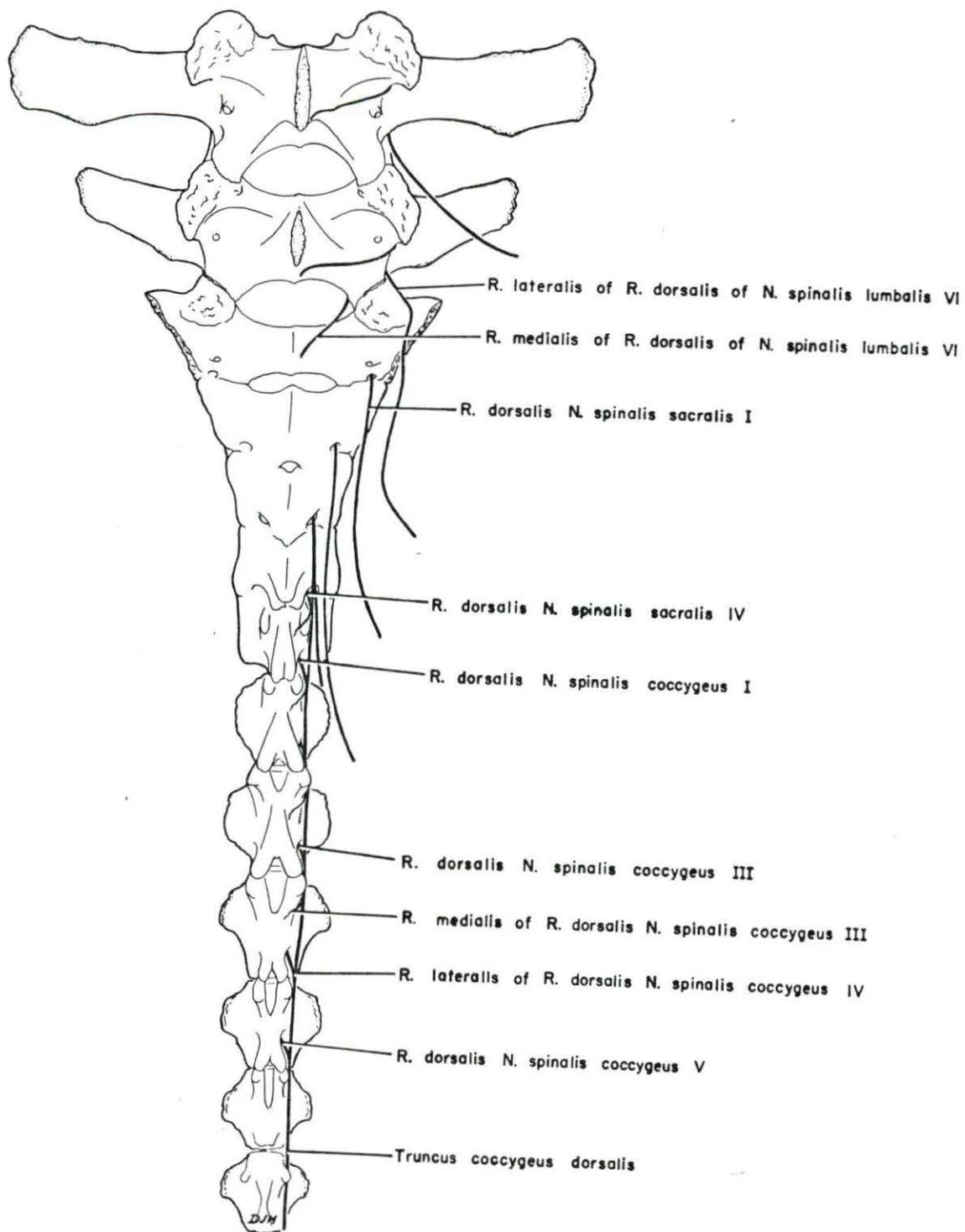


FIG. NO. 15b A schemetic ventral view showing the emergence of the Rami ventrales of Nn. spinales coccygei and the formation of the truncus coccygeus ventralis.

